

From: Google Calendar <calendar-notification@google.com>
Subject: Notification: Lolita/Toki site visit next Wed 9 am @ Wed Mar 9, 2022 8:30am - 2pm (EST) (ruth.ewing@noaa.gov)
To: Ruth Ewing - NOAA Federal
Sent: March 9, 2022 8:20 AM (UTC-05:00)

Lolita/Toki site visit next Wed 9 am

When Wed Mar 9, 2022 8:30am – 2pm Eastern Time - New York

[more details »](#)

Calendar ruth.ewing@noaa.gov

Who

- ruth.ewing@noaa.gov - organizer

Invitation from [Google Calendar](#)

You are receiving this email at the account ruth.ewing@noaa.gov because you are subscribed for notifications on calendar ruth.ewing@noaa.gov.

To stop receiving these emails, please log in to <https://calendar.google.com/calendar/> and change your notification settings for this calendar.

Forwarding this invitation could allow any recipient to send a response to the organizer and be added to the guest list, or invite others regardless of their own invitation status, or to modify your RSVP. [Learn More.](#)

From: Kimberly Damon-Randall - NOAA Federal <kimberly.damon-randall@noaa.gov>
Subject: visit follow up
To: tburke@thedolphinco.com
Cc: Ruth Ewing - NOAA Federal; Amy Sloan - NOAA Federal
Sent: March 16, 2022 4:06 PM (UTC-04:00)

Dear Travis,

Thank you again for the opportunity for NMFS to come to the Miami Seaquarium last week to meet with you and your staff and see Toki. We really appreciated the open discussions and also the opportunity for Dr. Ewing to check in periodically.

We look forward to a continued dialogue as things progress there. As we mentioned, Amy Sloan will be your NMFS primary point of contact. Please reach out to her regarding updates on Toki and with any questions you may have.

Thanks,
Kim

--

Kim Damon-Randall (pronouns: she/her/hers)
Director, Office of Protected Resources
NOAA Fisheries | U.S. Department of Commerce
1315 East-West Highway
Silver Spring, MD 20910
Kimberly.Damon-Randall@noaa.gov
office: 301-427-8400
cell: 301-233-3634



From: Travis Burke <tburke@thedolphinco.com>
Subject: Re: visit follow up
To: Kimberly Damon-Randall - NOAA Federal
Cc: Ruth Ewing - NOAA Federal; Amy Sloan - NOAA Federal
Sent: March 17, 2022 4:10 PM (UTC-04:00)

Good afternoon Kim,

It was a pleasure and honor to meet you and the team and share part of who we are.

It has been a busy couple weeks as you can imagine - absolutely excited to be in touch and will reach out to Amy to define reporting and visits.

Have a great day and thank you once again.

Respectfully,

Travis



WhatsApp (386) 986-5567

On Wed, Mar 16, 2022 at 4:07 PM Kimberly Damon-Randall - NOAA Federal <kimberly.damon-randall@noaa.gov> wrote:

Dear Travis,

Thank you again for the opportunity for NMFS to come to the Miami Seaquarium last week to meet with you and your staff and see Toki. We really appreciated the open discussions and also the opportunity for Dr. Ewing to check in periodically.

We look forward to a continued dialogue as things progress there. As we mentioned, Amy Sloan will be your NMFS primary point of contact. Please reach out to her regarding updates on Toki and with any questions you may have.

Thanks,
Kim

--

Kim Damon-Randall (pronouns: she/her/hers)
Director, Office of Protected Resources
NOAA Fisheries | U.S. Department of Commerce
1315 East-West Highway
Silver Spring, MD 20910
Kimberly.Damon-Randall@noaa.gov

office: 301-427-8400

cell: 301-233-3634



Instagram



commissionerregalado
Miami Seaquarium



50 likes

commissionerregalado Excited to see [@mayordlc](#) visiting our beloved Toki today [@miamiseaquarium_](#). The county is actively working with [@thedolphinco](#) to ensure Toki's healthy is a top priority!

View all 15 comments

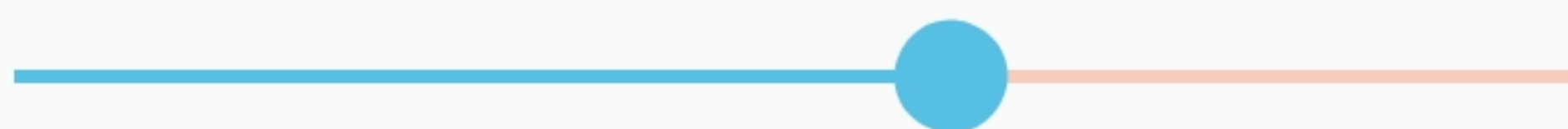

Add a comment...



4 hours ago





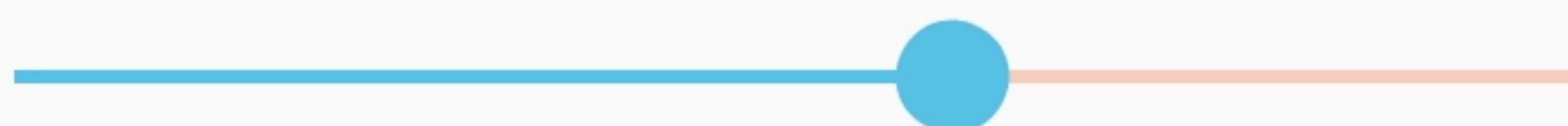Liked by **thechocolatecontessa** and **640 others**


mayordlc Today, I met with The Dolphin Company at [@miamiseaquarium_](#) and appreciate their willingness to discuss Toki's (Lolita) well-being.

Her health and safety is our top priority. As such, I echoed the wishes of our community in calling for an outside examination to assure her health.

5 hours ago





 Liked by **thechocolatecontessa** and **640 others**
mayordlc Today, I met with The Dolphin Company at [@miamiseaquarium_](#) and appreciate their willingness to discuss Toki's (Lolita) well-being.

Her health and safety is our top priority. As such, I echoed the wishes of our community in calling for an outside examination to assure her health.

5 hours ago



From: Amy Sloan - NOAA Federal <amy.sloan@noaa.gov>
Subject: Lolita (Tokitae) meeting next Fri
To: Ruth Ewing - NOAA Federal; Deborah Fauquier - NOAA Federal
Sent: March 24, 2022 3:42 PM (UTC-04:00)

Hi Ruth and Deb,
I scheduled a meeting next Friday April 1 to discuss Toki. Let us know if that day/time doesn't work.
Thanks,
Amy

Amy Sloan
Deputy Chief, Permits and Conservation Division
Office of Protected Resources

NOAA Fisheries | U.S. Department of Commerce
Mobile: 301-310-1062

<https://www.fisheries.noaa.gov/permits-and-forms#protected-resources>



From: Amy Sloan - NOAA Federal <amy.sloan@noaa.gov>
Subject: Re: Veterinary Visits
To: Travis Burke
Cc: Ruth Ewing - NOAA Federal; Kimberly Damon-Randall - NOAA Federal
Sent: April 4, 2022 4:41 PM (UTC-04:00)

Dear Travis,
Thank you for allowing Dr. Ewing to visit with Dr. Shelby Loos, see Toki, and be part of the Dignity Plan.

Dr. Ewing will communicate with Dr. Loos to coordinate visits and work plans and will keep us informed.

Sincerely,
Amy

Amy Sloan
Deputy Chief, Permits and Conservation Division
Office of Protected Resources

NOAA Fisheries | U.S. Department of Commerce
Mobile: 301-310-1062

<https://www.fisheries.noaa.gov/permits-and-forms#protected-resources>



On Fri, Apr 1, 2022 at 10:39 AM Travis Burke <tburke@thedolphinco.com> wrote:

Good morning Amy,

Thank you for all of your time.

The Miami Seaquarium is willing to allow Dr. Ruth Ewing to visit with Dr. Shelby Loos and be present.

The Miami Seaquarium is willing to allow Dr. Ruth Ewing to be part of the Dignity Plan.

My only ask is that Dr. Ewing communicate with Dr. Loos to coordinate visits and work plans and that they keep you and I informed.

Have a great day and thank you.

Respectfully,

Travis



WhatsApp (386) 986-5567

From: Travis Burke <tburke@thedolphinco.com>
Subject: Re: Veterinary Visits
To: Amy Sloan - NOAA Federal
Cc: Ruth Ewing - NOAA Federal; Kimberly Damon-Randall - NOAA Federal
Sent: April 4, 2022 5:35 PM (UTC-04:00)

Thank you - have a wonderful day.

Respectfully,

Travis



WhatsApp (386) 986-5567

On Mon, Apr 4, 2022 at 4:41 PM Amy Sloan - NOAA Federal <amy.sloan@noaa.gov> wrote:

Dear Travis,

Thank you for allowing Dr. Ewing to visit with Dr. Shelby Loos, see Toki, and be part of the Dignity Plan.

Dr. Ewing will communicate with Dr. Loos to coordinate visits and work plans and will keep us informed.

Sincerely,

Amy

Amy Sloan

*Deputy Chief, Permits and Conservation Division
Office of Protected Resources*

NOAA Fisheries | U.S. Department of Commerce
Mobile: 301-310-1062

<https://www.fisheries.noaa.gov/permits-and-forms#protected-resources>



On Fri, Apr 1, 2022 at 10:39 AM Travis Burke <tburke@thedolphinco.com> wrote:

Good morning Amy,

Thank you for all of your time.

The Miami Seaquarium is willing to allow Dr. Ruth Ewing to visit with Dr. Shelby Loos and be present.

The Miami Seaquarium is willing to allow Dr. Ruth Ewing to be part of the Dignity Plan.

My only ask is that Dr. Ewing communicate with Dr. Loos to coordinate visits and work plans and that they keep you and I informed.

Have a great day and thank you.

Respectfully,

Travis



WhatsApp (386) 986-5567

From: Amy Sloan - NOAA Federal <amy.sloan@noaa.gov>
Subject: Dr. Ewing visits
To: Travis Burke
Cc: Ruth Ewing - NOAA Federal; Kimberly Damon-Randall - NOAA Federal; Catherine Marzin - NOAA Federal
Sent: April 18, 2022 9:55 AM (UTC-04:00)

Dear Travis,

I hope this email finds you well. I'm sure you're aware that Dr. Ewing will be onsite today (April 18th) to be present during a routine follow-up medical work up and physical examination. Dr. Ewing met by phone with Drs. Loos and Reiderson on April 11th where it was determined that it would be beneficial for Dr. Ewing to be present during routine husbandry procedures at least once a month as Toki continues to improve clinically. Subsequent, monthly visits will be similarly coordinated with routine blood draws or other medical procedures (e.g., ultrasounds).

I've copied our Deputy Director, Catherine Marzin, who is acting for Kim this week.

Sincerely,
Amy

Amy Sloan
Deputy Chief, Permits and Conservation Division
Office of Protected Resources

NOAA Fisheries | U.S. Department of Commerce
Mobile: 301-310-1062

<https://www.fisheries.noaa.gov/permits-and-forms#protected-resources>



From: Travis Burke <tburke@thedolphinco.com>
Subject: Re: Dr. Ewing visits
To: Amy Sloan - NOAA Federal
Cc: Catherine Marzin - NOAA Federal; Kimberly Damon-Randall - NOAA Federal; Ruth Ewing - NOAA Federal
Sent: April 18, 2022 11:04 AM (UTC-04:00)

Good morning - thank you

Respectfully,

Travis

On Mon, Apr 18, 2022 at 09:55 Amy Sloan - NOAA Federal <amy.sloan@noaa.gov> wrote:

Dear Travis,

I hope this email finds you well. I'm sure you're aware that Dr. Ewing will be onsite today (April 18th) to be present during a routine follow-up medical work up and physical examination. Dr. Ewing met by phone with Drs. Loos and Reiderson on April 11th where it was determined that it would be beneficial for Dr. Ewing to be present during routine husbandry procedures at least once a month as Toki continues to improve clinically. Subsequent, monthly visits will be similarly coordinated with routine blood draws or other medical procedures (e.g., ultrasounds).

I've copied our Deputy Director, Catherine Marzin, who is acting for Kim this week.

Sincerely,
Amy

Amy Sloan
Deputy Chief, Permits and Conservation Division
Office of Protected Resources

NOAA Fisheries | U.S. Department of Commerce
Mobile: 301-310-1062

<https://www.fisheries.noaa.gov/permits-and-forms#protected-resources>



--
Respectfully, Travis The information contained in this message (including any attachments) is confidential and intended for the specific individual or entity to whom it is addressed and others authorized to receive it. If you are not the intended recipient, you should delete this message and are hereby notified that any disclosure, copying, or distribution of this message, or the taking of any action in reliance on the contents of this information is strictly prohibited and may be unlawful. If you have received this communication in error, please notify us immediately by responding to this email and then delete it from your system.

From: Amy Sloan - NOAA Federal <amy.sloan@noaa.gov>
Subject: Toki update and request for call Tue May 31
To: McKinnie, Carolyn - APHIS; Laurie.J.Gage@aphis.usda.gov
Cc: Goldentyer, Betty J - APHIS; Ruth Ewing - NOAA Federal; Deborah Fauquier - NOAA Federal; Jennifer Skidmore; Courtney Smith - NOAA Affiliate
Sent: May 27, 2022 12:31 PM (UTC-04:00)

Dear Carolyn and Laurie,

I reached out to Dr. Goldentyre, who gave me permission to request your participation on a team of Federal veterinarians to discuss the health and welfare of the captive Southern Resident killer whale, Toki (Tokitae/Lolita).

Miami Seaquarium has granted Dr. Ruth Ewing permission to come to Seaquarium on a regular basis to monitor Toki and discuss her condition and treatments with their veterinarian.

Please let me know if you're available **next Tuesday, May 31, either from 12:30-1:30 pm or 3-4 pm Eastern** for a call with our team to discuss some recent developments.

Thank you,
Amy

Amy Sloan
Deputy Chief, [Permits and Conservation](#)
Office of Protected Resources
NOAA Fisheries | U.S. Department of Commerce
Mobile: 301-310-1062



From: Ruth Ewing - NOAA Federal <ruth.ewing@noaa.gov>
Subject: Re: Site visit on Monday
To: Amy Sloan - NOAA Federal
Sent: August 10, 2022 5:24 PM (UTC-04:00)

ok

On Wed, Aug 10, 2022 at 4:52 PM Amy Sloan - NOAA Federal <amy.sloan@noaa.gov> wrote:
Thanks, I'm going to include our Toki team with APHIS (CJ and Laurie) along with Deb and Court (Jennifer is out of town).

On Wed, Aug 10, 2022 at 4:41 PM Ruth Ewing - NOAA Federal <ruth.ewing@noaa.gov> wrote:
Hi Amy,

Tuesday afternoon is likely the better day.

Regards,
Ruth

On Wed, Aug 10, 2022 at 3:35 PM Amy Sloan - NOAA Federal <amy.sloan@noaa.gov> wrote:
Thanks for letting me know.
Are you available for a short debrief Monday afternoon or Tuesday? Is there a time that works best for you?
Best,
Amy
Amy Sloan
Deputy Chief, [Permits and Conservation](#)
Office of Protected Resources
NOAA Fisheries | U.S. Department of Commerce
Mobile: 301-310-1062



On Wed, Aug 10, 2022 at 3:29 PM Ruth Ewing - NOAA Federal <ruth.ewing@noaa.gov> wrote:
Hi Amy,

I'll be conducting my site visit on Monday.

Ruth

From: Ruth Ewing - NOAA Federal <ruth.ewing@noaa.gov>
Subject: Re: Miami Seaquarium post
To: Amy Sloan - NOAA Federal
Sent: October 3, 2022 9:58 AM (UTC-04:00)

Hi Amy,

I was able to get a call into Shelby on Friday last week about 5pm. I'm hopping on a call now, but I can fill you in after.

Ruth

On Mon, Oct 3, 2022 at 9:51 AM Amy Sloan - NOAA Federal <amy.sloan@noaa.gov> wrote:

Hi Ruth,
See post below. I wanted to check in to see if you might be able to schedule a call with Shelby this week to get an update on Toki and inquire about having APHIS come out? I think it would be good if I could be on that call if okay with you. I can make my schedule work as needed if you can get time with Shelby for a call. Or, if you can set up a visit to go there in person, that is fine as well.

Also, FYI, I emailed Mridula and Jenny last week to inquire about your participation in carrying out the dignity plan and will let you know when I hear back (or they may let you know).

Let me know.
Thanks,
Amy

----- Forwarded message -----

From: Courtney Smith - NOAA Affiliate <courtney.smith@noaa.gov>
Date: Sun, Oct 2, 2022 at 5:35 PM
Subject: Miami Seaquarium post
To: Amy Sloan - NOAA Federal <amy.sloan@noaa.gov>, Jennifer Skidmore - NOAA Federal <jennifer.skidmore@noaa.gov>

Hi both,

Miami Seaquarium posted about Toki today on Facebook.

Verizon LTE

5:31 PM



Miami Seaquarium




3h ·

The dedication that our vets and animal care staff provide for our animals is unmatched. This couldn't be truer when it comes to the care of our beautiful Tokitae. We have a

special team, including world-renowned experts, that is dedicated to making sure Toki receives round-the-clock care.

Medication has stabilized Toki's health after the respiratory condition she experienced early this year. While not considered critical, her appetite has decreased. With guidance from Toki's vet, as well as the foremost marine mammal experts in the world, extra precautions are being taken.

Thank you for your interest in Toki; please send your positive vibes and prayers her way. We will provide updates on her condition as soon as we're able.



Home



Marketplace



Feeds



Notifications



Menu

| null



Miami Seaquarium




3h ·

The dedication that our vets and animal care staff provide for our animals is unmatched. This couldn't be truer when it comes to the care of our beautiful Tokitae. We have a special team, including world-renowned experts, that is dedicated to making sure Toki receives round-the-clock care.

Medication has stabilized Toki's health after the respiratory condition she experienced early this year. While not considered critical, her appetite has decreased. With guidance from Toki's vet, as well as the foremost marine mammal experts in the world, extra precautions are being taken.

Thank you for your interest in Toki; please send your positive vibes and prayers her way. We will provide updates on her condition as soon as we're able.



Home



Marketplace



Feeds



Notifications



Menu

From: Ruth Ewing - NOAA Federal <ruth.ewing@noaa.gov>
Subject: Re: Toki / Lolita news happening now
To: Lisa Belskis - NOAA Federal
Cc: Jenny Litz - NOAA Federal
Sent: December 13, 2022 2:30 PM (UTC-05:00)

Thanks Lisa.

On Tue, Dec 13, 2022 at 2:12 PM Lisa Belskis - NOAA Federal <lisa.belskis@noaa.gov> wrote:

Just an FYI. TV Channel 10 Local news is reporting that discussions are happening "at this hour" regarding Toki's health and what happens next.

[Miami Seaquarium '100% committed' to effort to free captive orca](#)

~Lisa B.

--

Lisa Belskis (she/hers)

Communications Manager (Acting)
[Southeast Fisheries Science Center](#)- Miami
[NOAA Fisheries](#)
lisa.belskis@noaa.gov
(786) 909-6079

[Sea Notes](#)

mmfs.sefsc.comms@noaa.gov

Twitter: [@NOAAFisheriesSE](#)

Facebook: [NOAA Fisheries](#)

Instagram: [noaafisheries](#)



The contents of this message are mine personally and do not necessarily reflect any position of NOAA.



From: Ruth Ewing - NOAA Federal <ruth.ewing@noaa.gov>
Subject: Lolita/Tokitae husbandry sampling
To: Shelby Loos
Bcc: Amy Sloan - NOAA Federal; Dawn Noren - NOAA Federal
Sent: February 2, 2023 3:32 PM (UTC-05:00)
Attached: Necropsy Body Morphometric measurements highlighted.pdf

Hi Shelby

As we discussed Monday. Please see below potential Cd-1 sampling

Researchers on the Southern Resident Killer Whale with NOAA Fisheries (NWFSC and SWFSC) would be interested in receiving samples/measurements that are currently being taken for solely for husbandry or diagnostic purposes, They are not able to request that the samples/measurements be taken at a higher frequency than currently being done until a revised permit is obtained.

To that end they wanted to optimize their sampling requests, with respect to her husbandry limits in order to be in compliance with what they are allowed to request.

For example, realizing that not all morphometric measurements are taken on Toki, Dawn Noren is interested to know if any of the ones currently being collected on her overlap with those in her protocol (attached -Assessing body condition via blubber and body measurements).

She is also very interested in comparing those measurements along with Toki's dietary records, which would be great, especially since she has periods of eating well and not eating well.

Dawn's unpublished data on her analysis of 12 months of continuous data from all of SeaWorld's killer whales shows that the body condition index that best reflects changes in blubber (from the 6 sites she measured) was the girth taken at the anterior pectoral fin insertion divided by body length.

Dawn offered up that information in case y'all wanted to evaluate the girths that they currently are collecting to compare to the ones you are following.

Specifically Dawn Noren (NWFSC) Requests:

1) Body condition measurements, 2) pool temp, 3) food records (see details in attached document).

Even without blubber thickness measurements (unless you wanted to share the US blubber thickness measure), the girth and length measurements will be very useful. According to her, her study at SeaWorld demonstrated that changes in the body condition indices do reflect changes in blubber thickness. Toki measurements will help her evaluate the range of values for the Southern Resident killer whale ecotype (taken via aerial photogrammetry and during necropsy) and how much variability there can be with changes in food intake.

This sounds like a relatively straight forward project to collaborate with Dawn on (plus or minus the blubber thicknesses that Tom follows - although it could be helpful for evaluating correlation between the measures)

Kim Parsons (NWFSC): genetics samples

1. whole blood - collected into EDTA - aliquot out 2mL to cryovial for -80 freezing and ship on dry ice.

Paul Chittaro: biological samples

1. serum - 2mL frozen -80 in cryovial ship on dry ice
2. fecal
3. muscle tissue from each prey species fed to Tokitae.
4. Ideally, #1,2,& 3 would be collected at several points in time, for example, once a month for 5 months.

Fecal and muscle samples: no preservatives. Ideally, frozen at -80 and shipped on dry ice.

I have access to a -80 freezer for temporary storage and I can negotiate the dry ice purchase and shipping with them so it is not a Seaquarium expense.

Please let me know if and when you are ready to pursue the aforementioned efforts.

Thanks,
Ruth

Project: Assessing body condition via blubber thickness and body morphometrics

P.I.: Dr. Dawn Noren (NOAA NWFSC)

Project goals

The purpose of this study is to assess the dynamics of blubber thickness and body condition indices (girths, body length, ratios of girths and length) to provide data to better interpret necropsy and photogrammetry data from wild stranded and free-swimming Southern Resident killer whales.

Measurements:

- 1) Weight
- 2) Total length (straight length measurement from tip of rostrum to fluke notch)
- 3) Four girths measured with measuring tape (see figure – girth sites are denoted by blue dashed lines)
 - a) Caudal aspect of the eye, at the cranial edge of the blowhole flap
 - b) Cranial pectoral fin insertion
 - c) Caudal pectoral fin insertion (Axilla)
 - d) Cranial dorsal fin insertion
- 4) Six skin and blubber thickness measurements taken by ultrasound and/or ruler insertion (please note measurement method). Measure blubber and skin separately. **Priority sites are 1 (Dorsal surface), 2 (Lateral surface), and 3 (Ventral surface) on the cranial dorsal fin insertion girth line** (see figure).



Body Mass (kg) _____

Straight Line Body Length (cm) _____

Girth (a) (cm) _____

Girth (b) (cm) _____

Girth (c) (cm) _____

Girth (d) (cm) _____

Site 1 Thickness (mm) skin: ____ blubber: _____

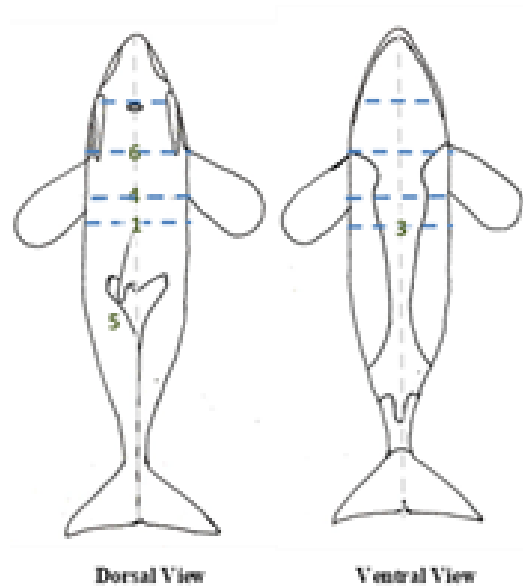
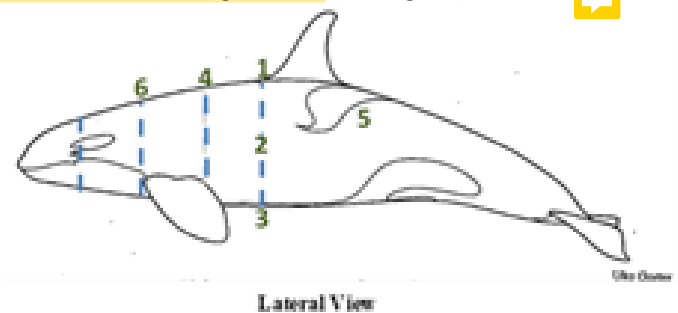
Site 2 Thickness (mm) skin: ____ blubber: _____

Site 3 Thickness (mm) skin: ____ blubber: _____

Site 4 Thickness (mm) skin: ____ blubber: _____

Site 5 Thickness (mm) skin: ____ blubber: _____

Site 6 Thickness (mm) skin: ____ blubber: _____



If there is adequate time, additional measurements can be made. Prioritize the bold appendage measurements. (The bold body measurements are already included above).

Revised May 15, 2014

APPENDIX XXIII: Morphometric analysis of stranded killer whales

Note: If there are time or constraints or safety issues, please collect at least the data points in **BOLD**

Observer _____ Date _____

Identification number _____ Gender _____ Weight _____

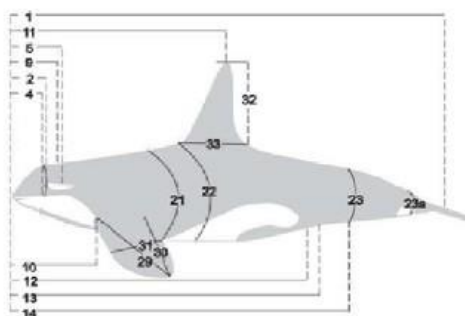
MEASUREMENTS, BODY (specify units of measure used _____)

1	Total straight length, snout to notch		13	Snout to genital slit	
2	Snout to center of eye (left)		14	Snout to anus	
3	Length of gape (left)		15	Eye to blowhole (center)(left)	
4	Snout to apex of melon		16	Projection of the lower jaw	
5	Snout to ear (left)		17	Blubber thickness*, mid dorsal	
6	Center of eye to ear (left)		18	Blubber thickness*, mid lateral	
7	Center of eye to angle of mouth		19	Blubber thickness*, mid ventral	
8	Center of eye to eye (curved - brow)		20	Girth at eye	
9	Snout to center of blowhole		21	Girth at axilla	
10	Snout to flipper (left)		22	Girth at leading edge of dorsal	
11	Snout to tip of dorsal fin		23	Girth at anus	
12	Snout to center of umbilicus		23a	Girth _____ cm before notch	

*Blubber thickness is measured at line 22- just cranial to the dorsal fin

MEASUREMENTS, APPENDAGES (specify units of measurement _____)

29	Flipper length (ant) (left)		33	Length of dorsal fin base	
30	Flipper length (post) (left)		34	Width of flukes (straight)	
31	Maximum width of flipper (left)		35	Length of flukes (left)	
32	Height of dorsal fin		36	Depth of fluke notch	



From: Ruth Ewing - NOAA Federal <ruth.ewing@noaa.gov>
Subject: Fwd: Lolita/Tokitae husbandry sampling
To: Dawn Noren - NOAA Federal
Cc: Amy Sloan - NOAA Federal
Sent: February 2, 2023 3:56 PM (UTC-05:00)

FYI - I'll let you know when I hear back from Shelby.

Ruth

----- Forwarded message -----

From: **Shelby Loos** <sloos@msq.cc>
Date: Thu, Feb 2, 2023 at 3:50 PM
Subject: Re: Lolita/Tokitae husbandry sampling
To: Ruth Ewing - NOAA Federal <ruth.ewing@noaa.gov>
Cc: Jessica Comolli <jcomolli@msq.cc>, Guillermo J. Sánchez Contreras <gsanchez@thedolphinco.com>

Hi Ruth,

Thank you for sending this! I am copying Dr. Jessica Comolli and Dr. Guillermo Sanchez as well so they are aware of these research contributions.

We can easily get these samples as we collect routine husbandry samples. We do not have a -80 though, I think you mentioned you know of one we could potentially use to store some of these samples until they are ready to ship? - please let me know the best way to move forward, we collect fecal and bloods weekly as of right now.

I will coordinate with the team to obtain her historical measurements and will see how many of these we can obtain going forward. Tom's current blubber measurement is not in the locations indicated, but we can start measuring them in the locations indicated in this protocol.

Dr. Jess - I've mentioned Dr. Ruth Ewing with NOAA that does monthly visits for Toki, she was here this past week but we will coordinate to make sure you are available for the next visit to get introduced!!

Thanks again!

Shelby

On Thu, Feb 2, 2023 at 3:34 PM Ruth Ewing - NOAA Federal <ruth.ewing@noaa.gov> wrote:

Hi Shelby

,

As we discussed Monday. Please see below potential Cd-1 sampling

Researchers on the Southern Resident Killer Whale with NOAA Fisheries (NWFSC and SWFSC) would be interested in receiving samples/measurements that are currently being taken for solely for husbandry or diagnostic purposes, They are not able to request that the samples/measurements be taken at a higher frequency than currently being done until a revised permit is obtained.

To that end they wanted to optimize their sampling requests, with respect to her husbandry limits in order to be in compliance with what they are allowed to request.

For example, realizing that not all morphometric measurements are taken on Toki, Dawn Noren is interested to

know if any of the ones currently being collected on her overlap with those in her protocol (attached -Assessing body condition via blubber and body measurements).

She is also very interested in comparing those measurements along with Toki's dietary records, which would be great, especially since she has periods of eating well and not eating well.

Dawn's unpublished data on her analysis of 12 months of continuous data from all of SeaWorld's killer whales shows that the body condition index that best reflects changes in blubber (from the 6 sites she measured) was the girth taken at the anterior pectoral fin insertion divided by body length.

Dawn offered up that information in case y'all wanted to evaluate the girths that they currently are collecting to compare to the ones you are following.

Specifically Dawn Noren (NWFSC) Requests:

1) Body condition measurements, 2) pool temp, 3) food records (see details in attached document).

Even without blubber thickness measurements (unless you wanted to share the US blubber thickness measure), the girth and length measurements will be very useful. According to her, her study at SeaWorld demonstrated that changes in the body condition indices do reflect changes in blubber thickness. Toki measurements will help her evaluate the range of values for the Southern Resident killer whale ecotype (taken via aerial photogrammetry and during necropsy) and how much variability there can be with changes in food intake.

This sounds like a relatively straight forward project to collaborate with Dawn on (plus or minus the blubber thicknesses that Tom follows - although it could be helpful for evaluating correlation between the measures)

Kim Parsons (NWFSC): genetics samples

1. whole blood - collected into EDTA - aliquot out 2mL to cryovial for -80 freezing and ship on dry ice.

Paul Chittaro: biological samples

1. serum - 2mL frozen -80 in cryovial ship on dry ice
2. fecal
3. muscle tissue from each prey species fed to Tokitae.
4. Ideally, #1,2,& 3 would be collected at several points in time, for example, once a month for 5 months.

Fecal and muscle samples: no preservatives. Ideally, frozen at -80 and shipped on dry ice.

I have access to a -80 freezer for temporary storage and I can negotiate the dry ice purchase and shipping with them so it is not a Seaquarium expense.

Please let me know if and when you are ready to pursue the aforementioned efforts.

Thanks,
Ruth

From: Ruth Ewing - NOAA Federal <ruth.ewing@noaa.gov>
Subject: Re: Miami Seaquarium
To: Jessica Comolli
Cc: Danay Voiles; Amy Sloan - NOAA Federal; Danay Voiles; Kelly Fischbach; Kimberly Damon-Randall - NOAA Federal
Sent: April 18, 2023 9:37 AM (UTC-04:00)

Thank you, I'll see you then.

Ruth

On Mon, Apr 17, 2023 at 9:15 PM Jessica Comolli <jcomolli@msq.cc> wrote:

Dr. Ewing tomorrow at noon is AOK by me. come to security (to the left of the front gate) and let them know you're here to see me and I'll come get you!

Sent from my iPhone

On Apr 17, 2023, at 8:10 PM, Ruth Ewing - NOAA Federal <ruth.ewing@noaa.gov> wrote:

Hello Dr. Comolli,

Thank you for reaching out. Would you mind if I came by tomorrow at about noon? I have previous engagements

later this week so Tuesday is the best time for me right now. Would that work for you?

I'll touch base with you in the morning to confirm.

Warmest regards,
Ruth Ewing, DVM
Veterinary Medical Officer
NOAA Fisheries
Marine Mammal and Turtle Division

On Mon, Apr 17, 2023 at 6:22 PM Jessica Comolli <jcomolli@msq.cc> wrote:

Good evening Dr. Ewing - it's very nice to "meet" you! Please let me know if there is anything you need from me contact wise. This is my email address.

Sent from my iPhone

On Apr 17, 2023, at 6:11 PM, Danay Voiles <dvoiles@msq.cc> wrote:

Good evening,

Hope all is well with you also. We do not have a current plan, as its in development with Lii. We are in discussions with Shedd Aquarium, Chicago about a potential transport and loan agreement for Loke and Elelo. Once this is determined we will share it with you.

I am not sure what Dr. Ewing needs to resume visits but on our end we have no issues. Dr. Jessica Comolli is copied on this email and can be copied on communications moving forward. We would be happy to assist you in any way we can.

I did receive the email earlier today and will review it now. Please let me know if you have any questions or concerns. Thank you.

On Mon, Apr 17, 2023 at 5:33 PM Amy Sloan - NOAA Federal <amy.sloan@noaa.gov> wrote:

Dear Mrs. Voiles,

I hope this email finds you well. We wanted to check in to see if you have any updates on the Pacific white-sided dolphins and to confirm that Dr. Ewing can resume her veterinary visits. We also wanted to make sure you received the email today from

"NIMM Inventory - NOAA Service Account <nimm.inventory@noaa.gov>" regarding updates to the Responsible Official and Primary Contact.

Sincerely,
Amy

Amy Sloan

Deputy Chief, [Permits and Conservation](#)

Office of Protected Resources

NOAA Fisheries | U.S. Department of Commerce

Mobile: 301-310-1062



On Mon, Apr 3, 2023 at 2:12 PM Amy Sloan - NOAA Federal <amy.sloan@noaa.gov> wrote:

Dear Ms. Voiles,

Thank you for your inquiry about potentially moving two Pacific white-sided dolphins (Loke and Elelo) to facilitate repairs to the dolphins' current habitat. You proposed moving Loke into the Whale Stadium tank with Toki and Li'i; it is not clear from your email whether you are also contemplating moving Elelo into the Whale Stadium tank as well. Attached for your reference is an email we sent last June to Travis Burke regarding a similar inquiry.

As we described in the attached correspondence with Mr. Burke, NMFS is concerned about a potential move of additional white-sided dolphins to Toki's tank. There have been previous reports of aggression by Toki when housed with multiple white-sided dolphins, and we understand that Toki's health can be impacted negatively by changes to her environment.

We believe that first, alternative options at Miami Seaquarium should be explored (see our questions below). If Elelo and Loke indeed need to be moved from their current pool to facilitate repairs, and there is no alternative tank other than Whale Stadium, Elelo should be relocated to a different facility (perhaps on loan to Shedd, as you mentioned), as he is a juvenile unknown to Toki. While we understand moving Loke, a geriatric animal (aged 40), to a different facility may not be optimal, we have concerns about Loke moving to Toki's tank, due to the reports of aggression and potential health effects. Additionally, we are concerned about the movement of yet another MMPA-regulated animal to an AWA-unregulated pool for any length of time.

We will need some additional information prior to responding to your request for approval to move Loke into the Whale Stadium.

- Is there any other tank retrofitted for cooling at Miami Seaquarium where Loke and Elelo could be moved?
- What repairs are needed in the Pacific white sided dolphin tank? What is the timeframe for the repairs?
- Is the new filtration and chiller system for the Whale Stadium operational?
- What are the current water quality conditions in the Whale Stadium tank?
- How long do you anticipate needing to have Loke in the tank with Toki and Li'i?
- What is the current health status of Toki, Li'i, and Loke?
- Would your staff be able to conduct 24-hour behavioral monitoring?
- What is the availability of the Attending Veterinarian?
- If potentially negative interactions are observed among the animals (e.g., chasing), or one of the animals becomes ill, do you have a tank available to immediately relocate Loke (and Li'i) if necessary?
- Do you have another contingency plan in place?

You requested our file on Toki/Li'i and the whale habitat. Attached are the Marine Mammal Data Sheets for Toki and Li'i. I would be happy to send you the additional correspondence between Travis Burke and myself. Please clarify if there are any other records you are requesting.

In addition, we would like to confirm that NMFS' Veterinary Medical Officer, Dr. Ruth Ewing, could continue to come to Miami Seaquarium to periodically see Toki and Li'i and discuss their health and welfare with the Attending Veterinarian. We understand that Dr. Loos is no longer on staff as an Attending Veterinarian. Moving forward, please let us know with whom Dr. Ewing should coordinate site visits and health updates.

Finally, you will be receiving an email from our National Inventory of Marine Mammals (NIMM) email account (nimm.inventory@noaa.gov) requesting an update to the primary contact for Miami Seaquarium.

Sincerely,

Amy

Amy Sloan

Deputy Chief, [Permits and Conservation](#)

Office of Protected Resources

NOAA Fisheries | U.S. Department of Commerce

Mobile: 301-310-1062



On Wed, Mar 22, 2023 at 3:50 AM Danay Voiles <dvoiles@dolphindiscovery.com> wrote:

Good morning,

I am reaching out on behalf of the Miami Seaquarium. My name is Danay Voiles and I am the new director here. I come from Dolphin Connection/Dolphin Company in the Keys. In Travis Burke's departure, I am now the point of contact for the park.

I have a few questions about the Pacific White Sided Dolphins in our care and in the Whale habitat as companion animals. I will ask below and if you can answer that would be greatly appreciated. If a call is best to discuss we can do that as well.

We are looking into an option of possibly moving our female Loke back into the whale habitat with Lii our male. They are a bonded parent pair and we see no issues with movement socially. The question is the feasibility of the movement from a regulation standpoint. I understand they are being created as the process moves forward so this may not be defined yet. The reasoning for the move is the current habitat needs repairs. We are willing to explore a loan to Shedd for our juvenile Pacific Whitesided but our goal is to keep Loke at MSQ if possible. If it isn't we understand, but want to make an informed decision.

Also, if you could share with me the file you have for the Seaquarium regarding Toki/Lii and whale habitat. Thank you so much in advance and I look forward to working with you.

--

Wishing you a wonderful day,
Mrs. Danay Voiles
Park Director- Miami Seaquarium
Park Director-Dolphin Connection Florida Keys



--

Wishing you a wonderful day,
Mrs. Danay Voiles
Park Director- Miami Seaquarium
Park Director-Dolphin Connection Florida Keys



From: Ruth Ewing - NOAA Federal <ruth.ewing@noaa.gov>
Subject: Re: Miami Seaquarium
To: Jessica Comolli
Cc: Danay Voiles; Amy Sloan - NOAA Federal; Danay Voiles; Kelly Fischbach; Kimberly Damon-Randall - NOAA Federal
Sent: April 17, 2023 8:10 PM (UTC-04:00)

Hello Dr. Comolli,

Thank you for reaching out. Would you mind if I came by tomorrow at about noon? I have previous engagements later this week so Tuesday is the best time for me right now. Would that work for you?

I'll touch base with you in the morning to confirm.

Warmest regards,
Ruth Ewing, DVM
Veterinary Medical Officer
NOAA Fisheries
Marine Mammal and Turtle Division

On Mon, Apr 17, 2023 at 6:22 PM Jessica Comolli <jcomolli@msq.cc> wrote:

Good evening Dr. Ewing - it's very nice to "meet" you! Please let me know if there is anything you need from me contact wise. This is my email address.

Sent from my iPhone

On Apr 17, 2023, at 6:11 PM, Danay Voiles <dvoiles@msq.cc> wrote:

Good evening,

Hope all is well with you also. We do not have a current plan, as its in development with Lii. We are in discussions with Shedd Aquarium, Chicago about a potential transport and loan agreement for Loke and Elelo. Once this is determined we will share it with you.

I am not sure what Dr. Ewing needs to resume visits but on our end we have no issues. Dr. Jessica Comolli is copied on this email and can be copied on communications moving forward. We would be happy to assist you in any way we can.

I did receive the email earlier today and will review it now. Please let me know if you have any questions or concerns. Thank you.

On Mon, Apr 17, 2023 at 5:33 PM Amy Sloan - NOAA Federal <amy.sloan@noaa.gov> wrote:
Dear Mrs. Voiles,

I hope this email finds you well. We wanted to check in to see if you have any updates on the Pacific white-sided dolphins and to confirm that Dr. Ewing can resume her veterinary visits. We also wanted to make sure you received the email today from "NIMM Inventory - NOAA Service Account <nimm.inventory@noaa.gov>" regarding updates to the Responsible Official and Primary Contact.

Sincerely,
Amy

Amy Sloan

Deputy Chief, [Permits and Conservation](#)
Office of Protected Resources
NOAA Fisheries | U.S. Department of Commerce
Mobile: 301-310-1062



On Mon, Apr 3, 2023 at 2:12 PM Amy Sloan - NOAA Federal <amy.sloan@noaa.gov> wrote:
Dear Ms. Voiles,

Thank you for your inquiry about potentially moving two Pacific white-sided dolphins (Loke and Elelo) to facilitate repairs to the dolphins' current habitat. You proposed moving Loke into the Whale Stadium tank with Toki and Li'i; it is not clear from your email whether you are also contemplating moving Elelo into the Whale Stadium tank as well. Attached for your reference is an email we sent last June to Travis Burke regarding a similar inquiry.

As we described in the attached correspondence with Mr. Burke, NMFS is concerned about a potential move of additional white-sided dolphins to Toki's tank. There have been previous reports of aggression by Toki when housed with multiple white-sided dolphins, and we understand that Toki's health can be impacted negatively by changes to her environment.

We believe that first, alternative options at Miami Seaquarium should be explored (see our questions below). If Elelo and Loke indeed need to be moved from their current pool to facilitate repairs, and there is no alternative tank other than Whale Stadium, Elelo should be relocated to a different facility (perhaps on loan to Shedd, as you mentioned), as he is a juvenile unknown to Toki. While we understand moving Loke, a geriatric animal (aged 40), to a different facility may not be optimal, we have concerns about Loke moving to Toki's tank, due to the reports of aggression and potential health effects. Additionally, we are concerned about the movement of yet another MMPA-regulated animal to an AWA-unregulated pool for any length of time.

We will need some additional information prior to responding to your request for approval to move Loke into the Whale Stadium.

- Is there any other tank retrofitted for cooling at Miami Seaquarium where Loke and Elelo could be moved?
- What repairs are needed in the Pacific white sided dolphin tank? What is the timeframe for the repairs?
- Is the new filtration and chiller system for the Whale Stadium operational?
- What are the current water quality conditions in the Whale Stadium tank?

- How long do you anticipate needing to have Loke in the tank with Toki and Li'i?
- What is the current health status of Toki, Li'i, and Loke?
- Would your staff be able to conduct 24-hour behavioral monitoring?
- What is the availability of the Attending Veterinarian?
- If potentially negative interactions are observed among the animals (e.g., chasing), or one of the animals becomes ill, do you have a tank available to immediately relocate Loke (and Li'i) if necessary?
- Do you have another contingency plan in place?

You requested our file on Toki/Li'i and the whale habitat. Attached are the Marine Mammal Data Sheets for Toki and Li'i. I would be happy to send you the additional correspondence between Travis Burke and myself. Please clarify if there are any other records you are requesting.

In addition, we would like to confirm that NMFS' Veterinary Medical Officer, Dr. Ruth Ewing, could continue to come to Miami Seaquarium to periodically see Toki and Li'i and discuss their health and welfare with the Attending Veterinarian. We understand that Dr. Loos is no longer on staff as an Attending Veterinarian. Moving forward, please let us know with whom Dr. Ewing should coordinate site visits and health updates.

Finally, you will be receiving an email from our National Inventory of Marine Mammals (NIMM) email account (nimm.inventory@noaa.gov) requesting an update to the primary contact for Miami Seaquarium.

Sincerely,

Amy

Amy Sloan

Deputy Chief, [Permits and Conservation](#)

Office of Protected Resources

NOAA Fisheries | U.S. Department of Commerce

Mobile: 301-310-1062



On Wed, Mar 22, 2023 at 3:50 AM Danay Voiles <dvoiles@dolphindiscovery.com> wrote:

Good morning,

I am reaching out on behalf of the Miami Seaquarium. My name is Danay Voiles and I am the new director here. I come from Dolphin Connection/Dolphin Company in the Keys. In Travis Burke's departure, I am now the point of contact for the park.

I have a few questions about the Pacific White Sided Dolphins in our care and in the Whale habitat as companion animals. I will ask below and if you can answer that would be greatly appreciated. If a call is best to discuss we can do that as well.

We are looking into an option of possibly moving our female Loke back into the whale habitat with Lii our male. They are a bonded parent pair and we see no issues with movement socially. The question is the feasibility of the movement from a regulation standpoint. I understand they are being created as the process moves forward so this may not be defined yet. The reasoning for the move is the current habitat needs repairs. We are willing to explore a loan to Shedd for our juvenile Pacific Whitesided but our goal is to keep Loke at MSQ if possible. If it isn't we understand, but want to make an informed decision.

Also, if you could share with me the file you have for the Seaquarium regarding Toki/Lii and whale habitat. Thank you so much in advance and I look forward to working with you.

--

Wishing you a wonderful day,
Mrs. Danay Voiles
Park Director- Miami Seaquarium
Park Director-Dolphin Connection Florida Keys



--

Wishing you a wonderful day,
Mrs. Danay Voiles
Park Director- Miami Seaquarium
Park Director-Dolphin Connection Florida Keys



From: Ruth Ewing - NOAA Federal <ruth.ewing@noaa.gov>
Subject: Re: Question re Toki visit
To: Amy Sloan - NOAA Federal
Cc: Courtney Smith - NOAA Affiliate; Jennifer Skidmore
Sent: June 13, 2023 5:01 PM (UTC-04:00)

I've never heard of these folks. Maybe it would help if they coordinate NOAA visits through your office as the contact.

Maybe that would help. Not to mention they would need to see their Government issued ID.

Ruth

On Tue, Jun 13, 2023 at 10:45 AM Amy Sloan - NOAA Federal <amy.sloan@noaa.gov> wrote:

Hi Ruth,

We were contacted by Charles Vinick on behalf of Eduardo Albor, asking if we were aware of a visit by Jay Norton, "NOAA marine mammal training coordinator" and Aubry Pullom, "senior marine mammal specialist," on Thursday at 7AM to discuss Tokitae's training procedures and discuss Tokitae's medical profile. The email references prior arrangements for the visit.

We do not know of Jay Norton nor Aubry Pullom being employed in NOAA (they are not in the NOAA directory) - are you familiar with them?

Thanks,
Amy

Amy Sloan

Deputy Chief, [Permits and Conservation](#)

Office of Protected Resources

NOAA Fisheries | U.S. Department of Commerce

Mobile: 301-310-1062



From: Ruth Ewing - NOAA Federal <ruth.ewing@noaa.gov>
Subject: Re: visit to Miami Seaquarium by NMFS trainer
To: Amy Sloan - NOAA Federal
Sent: June 14, 2023 1:06 PM (UTC-04:00)

Amy - did the person spoof a [NOAA.GOV](https://www.noaa.gov) email address too?

Ruth

On Wed, Jun 14, 2023 at 11:45 AM Amy Sloan - NOAA Federal <amy.sloan@noaa.gov> wrote:

Hi Charles,

Thank you for the email. We do not know a Jay Norton nor Aubry Pullom, and are not aware of them working for NOAA. We did not make arrangements for the visit.

Thanks,

Amy

Amy Sloan

Deputy Chief, [Permits and Conservation](#)

Office of Protected Resources

NOAA Fisheries | U.S. Department of Commerce

301-427-8432



On Tue, Jun 13, 2023 at 8:48 AM Charles Vinick <cvinick@mac.com> wrote:

Good morning Amy,

Eduardo Albor received an email that he asked me to inquire about. The email is from a Mr. Jay Norton, NOAA marine mammal training coordinator confirming a visit to the park by himself and Aubry Pullom, senior marine mammal specialist, on Thursday at 7AM to discuss Tokitae's training procedures and discuss Tokitae's medical profile. The email references prior arrangements for the visit and because neither we nor Mr. Albor had received anything in advance of the confirming email from Jay Norton, he requested that I check with you so that we can make appropriate arrangements for the visit.

Thank you and warm regards,

Charles

Charles Vinick

Friends of Toki

805-252-5421

cvinick@mac.com

From: Ruth Ewing - NOAA Federal <ruth.ewing@noaa.gov>
Subject: Fwd: Killer Whale Blubber Measurements via Ultrasound
To: Amy Sloan - NOAA Federal
Sent: June 20, 2023 8:00 AM (UTC-04:00)
Attached: Killer whale body condition study methods (9).pdf, Blubber thickness data sheet FINAL.docx

Hi Amy,

I wanted to loop you in on this email thread that came in from Dawn Noren. I neglected to notify our other NMFS contributors regarding Toki's care and health studies that there had been staffing changes at Miami Seaquarium.

This week I will be in Barataria Bay participating in the dolphin health assessment surveys, so I will be away from email for the most part with sporadic response when I'm able.

Regards,
Ruth

----- Forwarded message -----

From: Dawn Noren - NOAA Federal <dawn.noren@noaa.gov>
Date: Fri, Jun 16, 2023 at 8:06 PM
Subject: Re: Killer Whale Blubber Measurements via Ultrasound
To: Guillermo J. Sánchez Contreras <gsanchez@thedolphinco.com>
Cc: Jessica Comolli <jcomolli@msq.cc>, Ruth Ewing - NOAA Federal <ruth.ewing@noaa.gov>

Dear Drs. Sánchez and Comolli-

Thank you Dr. Sánchez for the prompt response, the introduction to Dr. Comolli, and the update on veterinarian staff at Miami Seaquarium.

I have attached the protocol with a diagram that describes the girths and the blubber thickness measurements we have collected from killer whales at SeaWorld. SeaWorld also provided me daily tank water temps, which we determined, along with season, influences blubber thickness. I can also forward you the email I sent to Dr. Loos with the example images from a Northern Resident killer whale female at SeaWorld that is about the same age as Toki, if that is helpful.

Besides providing additional measurements to evaluate Toki's body condition, which can be compared to those from other killer whales, data collected from Toki would help us understand how blubber thickness and body condition indices (ratios of girths and each girth/body length) change with health/food consumption to help us interpret body condition data collected on free-ranging Southern Resident killer whales (SRKW), which are endangered and face several risks, including reduced prey availability. Also, because Toki is a SRKW, it would be good to compare measurements from her to the 12-36+ months of measurements that have been collected from killer whales at the three SeaWorld facilities to evaluate how the body condition indices vary across distinct killer whale populations. While SeaWorld has one 100% Northern Resident killer whale, many of their whales are Icelandic or mixed, including some that have Southern Resident killer whale relatives.

If it is helpful to set up a call or virtual meeting, I would be happy to do so.

I have attached the SeaWorld protocol and I will also forward you an email that I sent to Dr. Loos with ultrasound images from the NRKW I mentioned.

Thanks,
Dawn

On Fri, Jun 16, 2023 at 2:32 PM Guillermo J. Sánchez Contreras <gsanchez@thedolphinco.com> wrote:

Dear Dr. Norren,

Thank you for your email. My name is Guillermo Sánchez, I am the Chief Veterinary Officer for The Dolphin Company. It is a pleasure to e-meet you.

Unfortunately Dr. Loos is no longer part of the Miami Seaquarium (MSQ) team. I am CCing Dr. Jessica Comolli, our Director of Animal Health at MSQ. Since Shelby left a couple of months ago, we lost a bit of consistency in the collection of the ultrasonographic data you mentioned but we are willing to resume the data collection. Would you share with us the images of the sites and the examples so we can plan accordingly?

Best regards,

Guille

El vie, 16 jun 2023 a las 15:25, Dawn Noren - NOAA Federal (<dawn.noren@noaa.gov>) escribió:

Hi Shelby-

I hope you are well. I wanted to check in to see if you have been able to collect any of the additional measurement sites from Toki or if you have data that can be shared? I am currently working with an intern to analyze the length and girth data from SeaWorld. I think she may have some time later this summer to analyze data from Toki, if available.

Even if the data is somewhat limited, it would be good to see how the data compare to the SeaWorld killer whales.

Thanks,
Dawn

On Tue, Feb 14, 2023 at 10:02 AM Shelby Loos <sloos@msq.cc> wrote:

Perfect, thank you! I do think including the extra sites will help us with our routine health monitoring, it will be good to have multiple sites for comparison and standardization compared to other animals. The only one that might be questionable as far as her behavior 6, so if she shows any aversiveness to us placing the probe there I won't push it and we will stick to the sites we can easily obtain and that she is already comfortable with. We also will only do this during the times we have a scheduled ultrasound, so won't be increasing the frequency outside of her routine monitoring plan.

Thanks again, I will let you know if I have any additional questions!

Shelby

On Tue, Feb 14, 2023 at 12:41 PM Dawn Noren - NOAA Federal (<dawn.noren@noaa.gov>) wrote:

Hi Shelby-

Thanks very much for your and the trainers' efforts. I attached a data sheet example. Data can also be recorded on an Excel sheet - with the same headings. Excel might be best for eventual data sorting/manipulation.

As far as the most important sites, they are 1, 2 and 3 because they correspond to the ones we take on wild killer whales during necropsy. However, since we know that a lot of the fat storage is in front of the pec fin, then 6 is pretty important. 4 is also a good one to measure.

5 by the saddle patch is the least important. Although getting site 3 is desired, sites 1 and 2 on that girth site are the most important since the dorsal area is a main area of fat storage and site 2 is a standard measurement site for many odontocete studies. I realize that doesn't really match with what is easiest to collect for you. Currently we are only allowed to get data from measurements that are collected for husbandry purposes (until our recent permit application is approved), so if these aren't sites that help you all for health monitoring and there is extra training involved, then it might be stretching what is allowable right now with no permit. Unless, you all decide that you would like to take these complete measurements to help with health monitoring. Then, getting these extra measurements will be allowed. As I mentioned, sites 6 and 4 are where the extra fat storage seems to be.

Thanks,
Dawn

On Tue, Feb 14, 2023 at 5:47 AM Shelby Loos <sloos@msq.cc> wrote:

Thank you, this is very helpful!! This is similar to what I am seeing on my ultrasound, I probably have to play around with my gain settings a little more though. I will reach out to Dr. Staggs to see if she has any helpful tips as well. I didn't see the fat layer on 2 and 4 on Toki, but she has one where I normally take her blubber measurement which makes the distinction clearer of where to measure. I only started this week though so it will likely take a few tries to get everything accurate!

You mention some sites are more important than others, which might those be? As of now, I can easily get sites 1,4, and 5. Site 6 will take some work because she is not used to having an ultrasound that far up on her head. Site 2 and 3 are a little more difficult because of our pool set up I have to reach out quite a bit so they might not be as accurate. We are also still working on her ultrasound line up, she only started learning ultrasound line ups a couple years ago but has been having a difficult time grasping that she needs to be still! So she is a bit of a moving target as well.

We will keep working at it!

Thanks for your help,

Shelby

On Mon, Feb 13, 2023 at 7:33 PM Dawn Noren - NOAA Federal <dawn.noren@noaa.gov> wrote:
Hello Dr. Loos-

Very nice to "meet you". Thanks very much for working on this! I really appreciate it. Some sites were definitely easier than the others. I've attached some images of the sites collected from a female Northern Resident killer whale that is around the same age as Toki. Note that the separate skin and blubber thickness measurements are noted.

Also, note that some of the attached files (site 2 and site 4) have a third measurement (#3) that the vet in San Diego attributed to a fat layer. Not all animals had these layers, and they weren't always consistently recorded for specific animals. Since they were only recorded for some San Diego animals, and when I compared all images, it didn't look like a consistent layer, I focused on blubber and skin only. Though admittedly, it is easier to differentiate layers when viewing live images because one can visualize how the layers move with breathing, etc. For the analysis, I am specifically interested in the blubber thickness (measurement 1), but also would like the skin thickness (measurement 2) recorded.

Do you happen to know Dr. Lydia Staggs at SeaWorld Orlando? She is the one that took the blubber measurements for me at that park location. She may have some helpful tips. I believe there were discussions among the vets at the three SeaWorld parks to devise methods to obtain the best images, including gain settings. The numbers on the file names correspond to the numbers on the diagram that was sent to you.

Please let me know if you have any questions or if you would like to discuss problematic measurement sites. Some sites are more important than others.

Thanks,
Dawn

On Sun, Feb 12, 2023 at 12:57 PM Shelby Loos <sloos@msq.cc> wrote:

Hello Dr. Noren!

I hope you are doing well. Dr. Ruth Ewing shared the protocol assessing body condition through blubber thickness in killer whales. I'm sure you are familiar with Toki, the killer whale we care for at the Miami Seaquarium. Routinely, we have measured her girth at the cranial dorsal fin insertion. We routinely measure her blubber layer at a location mid dorsal fin, cranial to but at the approximate level of the ovary. Here I can see a very distinct blubber layer on ultrasound. I started incorporating the other locations that you described into my ultrasound exams, however I can't seem to get a clear image of the blubber layer to obtain accurate measurements.

Do you have any ultrasound images you could share of those locations so that I can compare that my measurements are correct?

We are compiling all of the historical data we have and additional data going forward to be able to compare girth, blubber/skin thickness, pool temperature, diet, etc. that we hope to be able to share.

Thanks for your help!

Shelby

--

Shelby Loos, DVM

Staff Veterinarian



4400 Rickenbacker Causeway
Miami, Florida 33149
sloos@msq.cc

--

Dawn P. Noren, Ph.D.
Research Fishery Biologist
NOAA NMFS Northwest Fisheries Science Center
2725 Montlake Blvd. East
Seattle, WA 98112
(206) 302-2439
<https://www.fisheries.noaa.gov/contact/dawn-p-noren-adams-phd>

--

Dawn P. Noren, Ph.D.
Research Fishery Biologist
NOAA NMFS Northwest Fisheries Science Center
2725 Montlake Blvd. East
Seattle, WA 98112
(206) 302-2439
<https://www.fisheries.noaa.gov/contact/dawn-p-noren-adams-phd>

--

Dawn Noren
Research Fishery Biologist, Conservation Biology Division
Northwest Fisheries Science Center
NOAA Fisheries | U.S. Department of Commerce
Office: (206) 302-2439
www.fisheries.noaa.gov



Celebrating the 50th anniversary of the Endangered Species Act 1973 to 2023

--



--

Dawn Noren

Research Fishery Biologist, Conservation Biology Division
Northwest Fisheries Science Center
NOAA Fisheries | U.S. Department of Commerce
Office: (206) 302-2439
www.fisheries.noaa.gov



Celebrating the 50th anniversary of the Endangered Species Act 1973 to 2023

Project title

Assessing body condition via blubber thickness and body morphometrics

Project goals

The purpose of this study is to assess the dynamics of blubber thickness and body condition indices (girths, body length, ratios of girths and length) to provide data to better interpret necropsy and photogrammetry data from wild stranded and free-swimming killer whales. This study also provides information to SeaWorld on morphometric indices of growth and health status of killer whales.

Methods

Subjects and Collection Frequency: All killer whales at all U.S. parks measured monthly

All measurements taken using standard training techniques; participation by killer whales is voluntary.

Measurements:

- 1) Weight (taken on slide out, per typical husbandry methods)
- 2) Total length (straight length measurement from tip of rostrum to fluke notch; whale is measured with a measuring tape when it is straight and floating on its back in the water, per typical husbandry methods)
- 3) Four girths measured with measuring tape (see figure 1 – girth sites are denoted by blue dashed lines)
 - a) Caudal aspect of the eye, at the cranial edge of the blowhole flap (killer whale is measured while lying on ventral surface out of the water)
 - b) Cranial pectoral fin insertion (killer whale is measured while lying on ventral surface out of the water)
 - c) Caudal pectoral fin insertion (axillary region, killer whale is measured while in the water)
 - d) Cranial dorsal fin insertion (killer whale is measured while in the water)
- 4) Six skin and blubber thickness measurements are taken by ultrasound while the killer whale floats in the water (see figure 1 – skin thickness and blubber thickness sites (measured separately) are denoted by numbers 1-6)

Other Data: Daily pool water temperature records

Daily food records (species, amount in kg or lb (with units), caloric density of each species)

A.

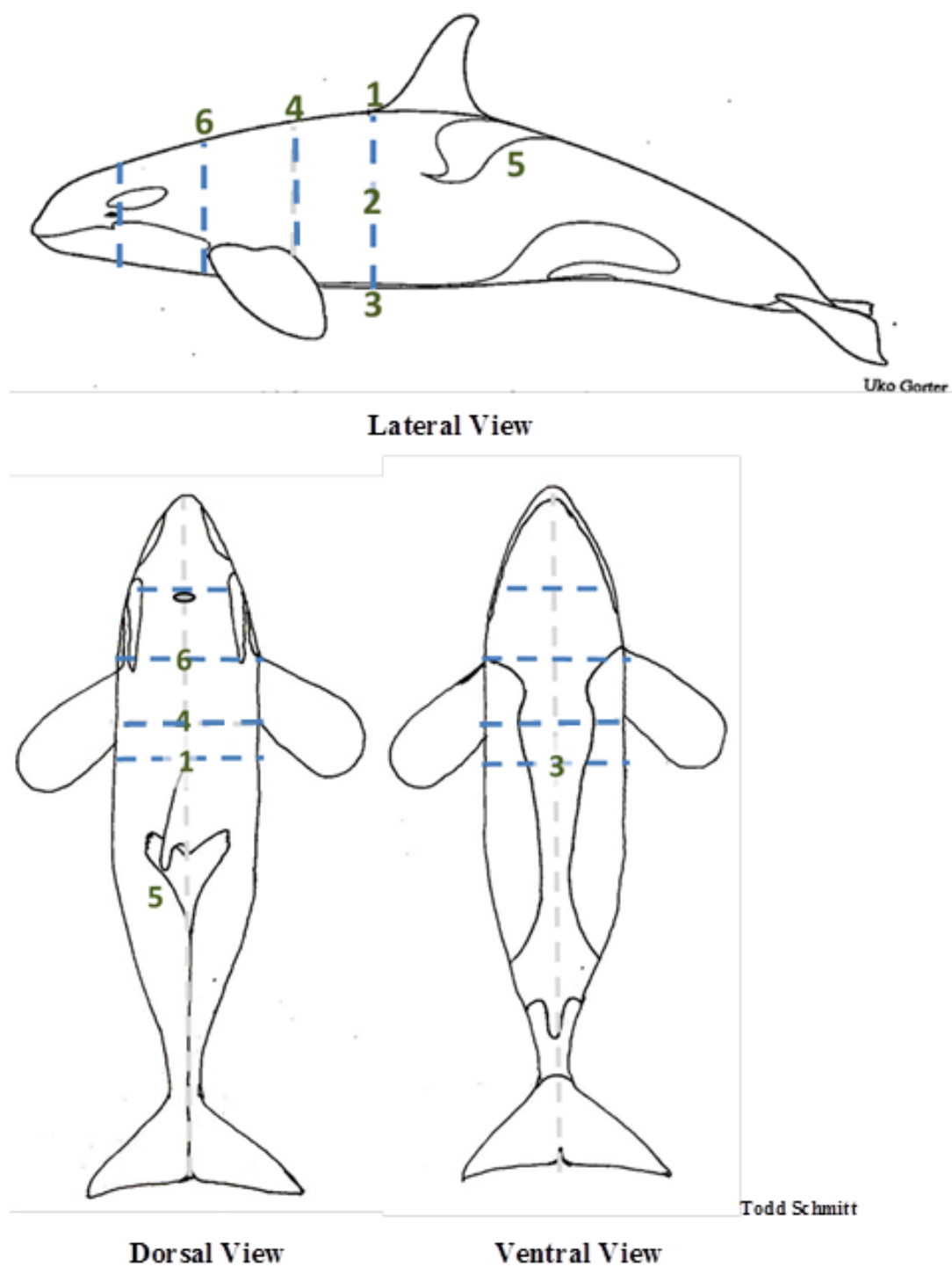


Figure 1. Girth and blubber thickness measurement sites on killer whales. Girths are measured at the blue dashed lines. Skin thickness and blubber thickness measurements are taken at sites denoted by the numbers 1-6.

From: Ruth Ewing - NOAA Federal <ruth.ewing@noaa.gov>
Subject: Re: Checking in
To: Amy Sloan - NOAA Federal
Sent: August 4, 2023 5:49 PM (UTC-04:00)

Hi Amy,

Dr. Jess contacted me this morning to see if I could come over today. I was originally planning on going next week but I went and spent the afternoon over there.

I'm available on Monday at 10am if you want to have a quick call.

Ruth

On Fri, Aug 4, 2023 at 1:59 PM Amy Sloan - NOAA Federal <amy.sloan@noaa.gov> wrote:

Dear Danay,

I hope this email finds you well. I'm writing to check in following our previous correspondence.

We see that on July 12th Friends of Toki updated their [website](#), stating: *“Although the stadium is in poor condition and is not open to the public, the pool itself does not appear to be a risk to her and appears to not be in structural jeopardy.”* The Friends of Toki website also says they have a plan and team in place to remain onsite if a hurricane hits Miami.

Since Miami Seaquarium is currently the legal custodian of Toki, we would like to discuss possible alternative short-term locations to ensure Toki's safety, especially during the 2023 Atlantic hurricane season. As you may be aware, we received a Congressional inquiry on this matter.

Please let me know if you are available for a call next week to discuss, and what day and time would work best for you.

Sincerely,

Amy

Amy Sloan

Deputy Chief, [Permits and Conservation](#)

Office of Protected Resources

NOAA Fisheries | U.S. Department of Commerce

Office: 301-427-8432

Mobile: 301-310-1062

[Celebrating 50 years of the Endangered Species Act!](#)



From: Ruth Ewing - NOAA Federal <ruth.ewing@noaa.gov>
Subject: Fwd: Tokitae samples
To: Ruth Ewing
Sent: August 18, 2023 9:20 PM (UTC-04:00)
Attached: NOAA NMFS_Toki Research Samples_FINAL.xlsx, Noren NOAA NWFSC Morphometric measurements.pdf, Noren NOAA NWFSC muscle sample protocol.pdf, Orca-necropsy-protocol-FINAL-May-15-2014.pdf

----- Forwarded message -----

From: Dawn Noren - NOAA Federal <dawn.noren@noaa.gov>
Date: Fri, Aug 18, 2023 at 8:53 PM
Subject: Re: Tokitae samples
To: Guillermo J. Sánchez Contreras <gsanchez@thedolphinco.com>
Cc: Brad Hanson - NOAA Federal <brad.hanson@noaa.gov>, Jessica Comolli <jcomolli@msq.cc>, Kim Parsons - NOAA Federal <kim.parsons@noaa.gov>, Lynne Barre - NOAA Federal <Lynne.Barre@noaa.gov>, Ruth Ewing - NOAA Federal <ruth.ewing@noaa.gov>

Hi Guille-

Thanks for your help. I attached a master list on Excel for the samples requested by NOAA National Marine Fisheries Service Science Center labs, the morphometrics measurement protocol, the muscle sample protocol that shows the sampling location, and the killer whale necropsy protocol. Some of the sample lists in that necropsy protocol are a bit outdated, so the primary list for samples is the Excel sheet and morphometrics protocol.

Thanks,
Dawn

On Fri, Aug 18, 2023 at 3:37 PM Guillermo J. Sánchez Contreras <gsanchez@thedolphinco.com> wrote:
Hi Dawn,

Thanks!

Send us the protocol and list and we will do our best to collect the samples and gather the info requested.

Best regards,

Guille

El El vie, 18 de agosto de 2023 a las 18:17, Dawn Noren - NOAA Federal <dawn.noren@noaa.gov> escribió:
Dear Guille and Jessica-

I just heard the unfortunate news about Tokitae's passing. My condolences to all who were involved in her care. I am inquiring to see if there will be a necropsy and samples taken. If so, I was wondering if it would be possible to make requests.

We have been working with Dr. Ruth Ewing from NOAA Fisheries in Miami to maintain a sample request list that addresses several research questions related to Southern Resident killer whale biology and conservation. We are also interested in obtaining the blubber and skin thicknesses, girths, and body length measurements from the protocol that we had discussed last month.

Please let me know if you will consider these requests and if you would like me to send the list and sampling protocols.

Thanks
Dawn

--
Dawn Noren

Research Fishery Biologist, Conservation Biology Division

Northwest Fisheries Science Center

NOAA Fisheries | U.S. Department of Commerce

Office: (206) 302-2439

www.fisheries.noaa.gov

Celebrating the 50th anniversary of the Endangered Species Act 1973 to 2023

--
Guillermo Sánchez Contreras
Director of Veterinary Services & Research
The Dolphin Company

--
Dawn Noren
Research Fishery Biologist, Conservation Biology Division
Northwest Fisheries Science Center
NOAA Fisheries | U.S. Department of Commerce
Office: (206) 302-2439
www.fisheries.noaa.gov



Celebrating the 50th anniversary of the Endangered Species Act 1973 to 2023

Tissue Type	Sample Size Requested	Notes	Storage container	Storage method	Investigator Receiving/Analyzing Samples	Investigator Affiliation/ NOAA Lab	Associated Permit for Transport and Receipt of Part for Research Purposes
MORPHOMETRICS AND BLUBBER AND SKIN THICKNESS PROTOCOL		See protocol and data sheet in included PDF			Dr. Dawn Noren	NWFSC	21348
Blowhole swab	swab	molecular analysis (not culture)	Whirl-pak or dry swab tube (no media)	-28°C (dry ice ship) or RNALater (room temp)	Dr. Dawn Noren	NWFSC	21348
Skin only	1cm X 1cm		tissue culture media	+4°C (ship at room temperature)	Dr. Phil Morin	SWFSC	22306
Full depth skin+blubber with top edge of muscle	10 cm X 10 cm Square		wrapped in foil and bagged	-80C (ship on dry ice)	Dr. Irv Schultz	NWFSC	21348
Full depth skin+blubber with top edge of muscle	5 cm X 5 cm Square	dorsal surface, just posterior to the posterior dorsal fin insertion	wrapped in foil and bagged	-80C (ship on dry ice)	Dr. Kim Parsons	NWFSC	21348
Full depth skin+blubber with top edge of muscle	5 cm X 5 cm Square (n=3 sites)	dorsal, lateral and ventral surfaces, anterior to the dorsal fin (along girth ring where blubber is measured at sites 1, 2, and 3)	wrapped in foil and bagged	-80C (ship on dry ice)	Dr. Dawn Noren	NWFSC	21348
1cm depth skin+blubber	1 cm X 1 cm Square		cryovial	-80C (ship on dry ice)	Dr. Phil Morin	SWFSC	22306
Blood (whole)	2-3 ml whole blood		w/EDTA as anticoagulant	-80C (ship on dry ice)	Dr. Kim Parsons	NWFSC	21348
Blood (serum)	10-20 ml serum		BD serum collection tubes https://www.bd.com	-80C (ship on dry ice)	Dr. Irv Schultz	NWFSC	21348
Longissimus dorsi muscle (mid-belly of muscle, anterior)	10 cm X 10 cm X 10 cm Block	See protocol and fig in included PDF	wrapped in foil and bagged	-80C (ship on dry ice)	Dr. Dawn Noren	NWFSC	21348
Muscle	1cm X 1cm		cryovial	-80C (ship on dry ice)	Dr. Phil Morin	SWFSC	22306
Muscle	1cm X 1cm		cryovial	RNALater (ship room temp)	Dr. Phil Morin	SWFSC	22306
Brain	1cm X 1cm		cryovial	-80C (ship on dry ice)	Dr. Phil Morin	SWFSC	22306
Brain	1cm X 1cm		cryovial	RNALater (ship room temp)	Dr. Phil Morin	SWFSC	22306
Brain	30-50 g		wrapped in foil, frozen immediately	-80C (ship on dry ice)	Dr. Irv Schultz	NWFSC	21348
Conjunctiva swab	swab	molecular analysis (not culture)	Whirl-pak or dry swab tube (no media)	-80°C (dry ice ship) or RNALater (room temp)	Dr. Dawn Noren	NWFSC	21348
Eye	1cm X 1cm	whole eye or section of retina	tissue culture media	+4°C (ship at room temperature)	Dr. Phil Morin	SWFSC	22306
Oropharynx swab	swab	molecular analysis (not culture)	Whirl-pak or dry swab tube (no media)	-80°C (dry ice ship) or RNALater (room temp)	Dr. Dawn Noren	NWFSC	21348
Trachea swab	swab	molecular analysis (not culture)	Whirl-pak or dry swab tube (no media)	-80°C (dry ice ship) or RNALater (room temp)	Dr. Dawn Noren	NWFSC	21348
Trachea	1cm X 1cm	connective tissue only	tissue culture media	+4°C (ship at room temperature)	Dr. Phil Morin	SWFSC	22306
Lung Swab	swab	molecular analysis (not culture)	Whirl-pak or dry swab tube (no media)	-80°C (dry ice ship) or RNALater (room temp)	Dr. Dawn Noren	NWFSC	21348
Lung	1cm X 1cm		cryovial	-80C (ship on dry ice)	Dr. Phil Morin	SWFSC	22306
Lung	1cm X 1cm		tissue culture media	+4°C (ship at room temperature)	Dr. Phil Morin	SWFSC	22306
Lung	1cm X 1cm		cryovial	RNALater (ship room temp)	Dr. Phil Morin	SWFSC	22306
Heart	1cm X 1cm		cryovial	-80C (ship on dry ice)	Dr. Phil Morin	SWFSC	22306
Heart	1cm X 1cm		tissue culture media	+4°C (ship at room temperature)	Dr. Phil Morin	SWFSC	22306
Heart	1cm X 1cm		cryovial	RNALater (ship room temp)	Dr. Phil Morin	SWFSC	22306
Liver	1cm X 1cm		cryovial	-80C (ship on dry ice)	Dr. Phil Morin	SWFSC	22306
Liver	1cm X 1cm		cryovial	RNALater (ship room temp)	Dr. Phil Morin	SWFSC	22306
Spleen	1cm X 1cm		cryovial	-80C (ship on dry ice)	Dr. Phil Morin	SWFSC	22306
Spleen	1cm X 1cm		cryovial	RNALater (ship room temp)	Dr. Phil Morin	SWFSC	22306
Kidney	30-50 g		wrapped in foil, frozen immediately	-80C (ship on dry ice)	Dr. Irv Schultz	NWFSC	21348
Bile	10-30 ml		glass storage tube preferable	-80C (ship on dry ice)	Dr. Irv Schultz	NWFSC	21348
Intestine	1cm X 1cm		tissue culture media	+4°C (ship at room temperature)	Dr. Phil Morin	SWFSC	22306
Feces	30-50 g		capped plastic container or glass jar	-80C (ship on dry ice)	Dr. Irv Schultz	NWFSC	21348
Gonad	1cm X 1cm		cryovial	-80C (ship on dry ice)	Dr. Phil Morin	SWFSC	22306
Gonad	1cm X 1cm		tissue culture media	+4°C (ship at room temperature)	Dr. Phil Morin	SWFSC	22306
Gonad	1cm X 1cm		cryovial	RNALater (ship room temp)	Dr. Phil Morin	SWFSC	22306
Dr. Ruth Ewing, SEFSC, will be the sample collector and shipper							

Project: Assessing body condition via blubber thickness and body morphometrics

P.I.: Dr. Dawn Noren (NOAA NWFSC)

Project goals

The purpose of this study is to assess the dynamics of blubber thickness and body condition indices (girths, body length, ratios of girths and length) to provide data to better interpret necropsy and photogrammetry data from wild stranded and free-swimming Southern Resident killer whales.

Measurements:

- 1) Weight
- 2) Total length (straight length measurement from tip of rostrum to fluke notch)
- 3) Four girths measured with measuring tape (see figure – girth sites are denoted by blue dashed lines)
 - a) Caudal aspect of the eye, at the cranial edge of the blowhole flap
 - b) Cranial pectoral fin insertion
 - c) Caudal pectoral fin insertion (Axilla)
 - d) Cranial dorsal fin insertion
- 4) Six skin and blubber thickness measurements taken by ultrasound and/or ruler insertion (please note measurement method). Measure blubber and skin separately. Priority sites are 1 (Dorsal surface), 2 (Lateral surface), and 3 (Ventral surface) on the cranial dorsal fin insertion girth line (see figure).

Body Mass (kg) _____

Straight Line Body Length (cm) _____

Girth (a) (cm) _____

Girth (b) (cm) _____

Girth (c) (cm) _____

Girth (d) (cm) _____

Site 1 Thickness (mm) skin: ____ blubber: _____

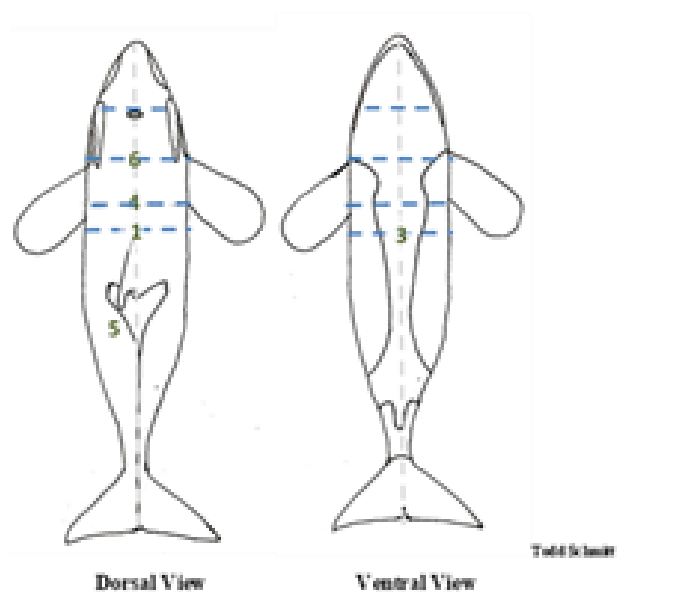
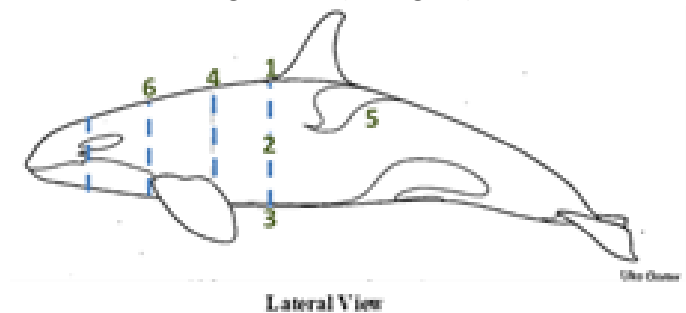
Site 2 Thickness (mm) skin: ____ blubber: _____

Site 3 Thickness (mm) skin: ____ blubber: _____

Site 4 Thickness (mm) skin: ____ blubber: _____

Site 5 Thickness (mm) skin: ____ blubber: _____

Site 6 Thickness (mm) skin: ____ blubber: _____



If there is adequate time, additional measurements can be made. Prioritize the bold appendage measurements. (The bold body measurements are already included above).

Revised May 15, 2014

APPENDIX XXIII: Morphometric analysis of stranded killer whales

Note: If there are time or constraints or safety issues, please collect at least the data points in **BOLD**

Observer _____ Date _____

Identification number _____ Gender _____ Weight _____

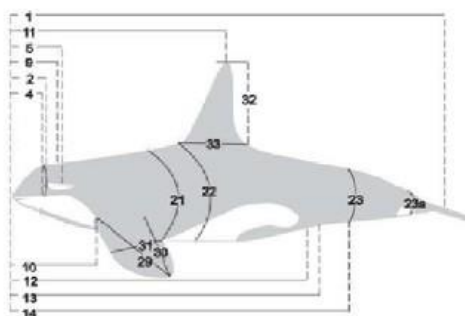
MEASUREMENTS, BODY (specify units of measure used _____)

1	Total straight length, snout to notch		13	Snout to genital slit	
2	Snout to center of eye (left)		14	Snout to anus	
3	Length of gape (left)		15	Eye to blowhole (center)(left)	
4	Snout to apex of melon		16	Projection of the lower jaw	
5	Snout to ear (left)		17	Blubber thickness*, mid dorsal	
6	Center of eye to ear (left)		18	Blubber thickness*, mid lateral	
7	Center of eye to angle of mouth		19	Blubber thickness*, mid ventral	
8	Center of eye to eye (curved - brow)		20	Girth at eye	
9	Snout to center of blowhole		21	Girth at axilla	
10	Snout to flipper (left)		22	Girth at leading edge of dorsal	
11	Snout to tip of dorsal fin		23	Girth at anus	
12	Snout to center of umbilicus		23a	Girth _____ cm before notch	

*Blubber thickness is measured at line 22- just cranial to the dorsal fin

MEASUREMENTS, APPENDAGES (specify units of measurement _____)

29	Flipper length (ant) (left)		33	Length of dorsal fin base	
30	Flipper length (post) (left)		34	Width of flukes (straight)	
31	Maximum width of flipper (left)		35	Length of flukes (left)	
32	Height of dorsal fin		36	Depth of fluke notch	



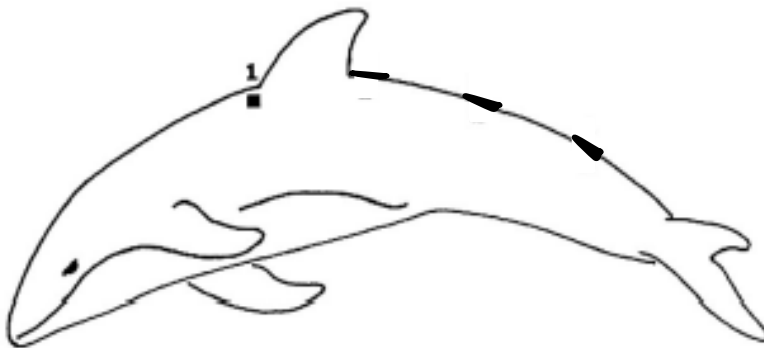
Dawn Noren, Research Fishery Biologist, NOAA NMFS Northwest Fisheries Science Center, Seattle, WA

Office: 206-302-2439

Cell: 206-423-0215

E-mail: dawn.noren@noaa.gov

Muscle myoglobin content and acid buffering capacity quantification to assess variability in muscle biochemistry and diving capability with development and across killer whale ecotypes. Collect muscle samples from all carcasses (including fetuses, neonates, and juveniles) that are in fresh condition (Smithsonian Condition Code 2). Samples are to be collected from the midbelly of the primary locomotor muscle (*m. longissimus dorsi*), following Noren and Williams 2000 (Site 1 in the figure below). The location of the sampling site is below the anterior insertion site of the dorsal fin. Samples (10X10X10 cm block) should be completely wrapped in foil, placed in a Ziploc bag, and frozen immediately after collection.



Noren SR, Williams TM (2000) Body size and skeletal muscle myoglobin of cetaceans: Adaptations for maximizing dive duration. *Comp Biochem Physiol A* 126:181–191

KILLER WHALE NECROPSY AND DISEASE TESTING PROTOCOL

Updated May 15, 2014

**Stephen A. Raverty, DVM, MSc, PhD, Diplomate ACVP^{1,2}, Joseph K. Gaydos, VMD, PhD³ and
Judy A. St. Leger, DVM, Diplomate ACVP⁴**

¹Animal Health Center, Ministry of Agriculture, Abbotsford, British Columbia, Canada

²Marine Mammal Research Unit, University of British Columbia, Vancouver, B.C. Canada

³SeaDoc Society, UC Davis Wildlife Health Center — Orcas Island Office, Eastsound, Washington State, USA

⁴SeaWorld Parks and Entertainment, San Diego, California, USA

**NOTE: If you are heading to the field to necropsy a killer whale, please print
Appendices XXII-XXVII (pages 66–82) and take them with you!**



Live Stranded Killer Whale in Hawaii, Photo courtesy of Jessica Aschettino, NOAA/NMFS/PIRO Permit #932-1489-09

**If tissues are not collected at the time of necropsy,
the opportunity to appropriately sample the animal is lost.**

This protocol is a guide for that collection.

Revised May 15, 2014

Table of Contents

SIGNIFICANT PATHOGEN ALERT:	3
CETACEAN BRUCELLA:	3
CETACEAN MORBILLIVIRUS:	4
INFLUENZA:	5
SALMONELLA:	5
APICOMPLEXANS:	5
PREVIOUSLY REPORTED PATHOGENS:	6
INTRODUCTION:	7
EQUIPMENT CHECKLIST:	9
LOGISTICS AND NECROPSY RECOMMENDATIONS	10
SAFETY	10
NECROPSY TEAM ROLES	11
EXTERNAL EXAM AND PRE-DISSECTION SAMPLING	11
DECOMPOSITION TABLE:	12
IMAGING CONSIDERATIONS	12
SKELETAL EXAMINATION AND PREPARATION CONSIDERATIONS	13
ACKNOWLEDGMENTS	14
LITERATURE CITED:	14
KILLER WHALE NECROPSY PROTOCOL COMPREHENSIVE KILLER WHALE TISSUE SAMPLE CHECKLIST	18
APPENDIX I: Sample Priorities based on Tissue Condition	24
HIGH PRIORITY SAMPLES:	24
INTERMEDIATE PRIORITY SAMPLES:	25
LOW PRIORITY SAMPLES:	25
APPENDIX II: Pathogens reported in killer whales	27
Table 1: Pathogens detected directly or via serology in killer whales	27
Table 2: Endoparasites identified or suggested by serology in killer whales	28
APPENDIX III: The One Hour Necropsy Protocol	29
APPENDIX IV: Researchers requesting killer whale tissues	30
APPENDIX IVB: Request for marine mammal post-mortem samples	34
APPENDIX V: Permitting concerns and authorities	35
APPENDIX VI: Pathogen and tissue sample list for Polymerase Chain Reaction Studies	36
APPENDIX VII: Marine mammal blubber sampling protocol	38
APPENDIX VIII: Collection of samples for contaminant analysis	40
APPENDIX IX: Collection of samples for biotoxin analysis	41
APPENDIX X: Webpage resources for submission forms	43
APPENDIX XI: Photography instructions and considerations	44

Revised May 15, 2014

APPENDIX XII: Ancillary imaging instructions	45
APPENDIX XIII: Oil spill concerns and sampling	46
APPENDIX XIV: Considerations and sampling for live stranded killer whales	48
APPENDIX XV: Cetacean ear extraction and fixation protocol	50
APPENDIX XVI: Barotrauma considerations and sampling protocol for gas bubbles	54
Appendix XVII: Dorsal fin measurement and collection request	56
APPENDIX XVIII: Archiving tissue samples	58
APPENDIX XIX: Lesion Description Form	59
APPENDIX XX: NOAA Fisheries NW Region Killer Whale Stranding Protocol	60
*For killer whale strandings in other parts of the world	64
Appendix XXI: Protocol for examining killer whales for signs of human interaction	65
APPENDIX XXII: Fetal examination and sample management	66
APPENDIX XXIII: Morphometric analysis of stranded killer whales	68
APPENDIX XXIV: Gross pathology data recording form	69
APPENDIX XXV: Checklist - tissues to collect from a Code 2 or 3 killer whale carcass	77
APPENDIX XXVI: Checklist - tissues to collect from a Code 4 killer whale carcass	79
APPENDIX XXVII: Checklist - tissues to collect from a Code 5 killer whale carcass	81
Photo Identifier:	82

SIGNIFICANT PATHOGEN ALERT:

Pathogens acquire significance because they cause harm to humans or animals. Examination of deceased animals has inherent safety concerns. Certain pathogens such as *Brucella* sp., influenza, and arboviruses warrant elevated vigilance and care. Likewise, rapid detection of fatal, transmissible agents that may impact killer whale population health is critical to inform management activity. Chief among these pathogen of concern are *Brucella* spp., cetacean morbillivirus, influenza, *Salmonella* spp., and apicomplexans.

CETACEAN BRUCELLA:

Marine mammal associated *Brucella* spp. that differ from recognized named species within the genus have been increasingly detected in a number of pinnipeds and cetaceans in the United Kingdom, New Zealand, the United States and Canada (Ross et al., 1996; Foster et al., 1996; Nielsen et al., 2001; Van Bressemer et al., 2001a). Antibodies to *Brucella* spp. have been identified in post mortem heart blood and in live captured (A73) killer whale with no attendant pathology or clinical disease (Jepson et al., 1997; Raverty et al., 2004).

Infection by *Brucella* has resulted in placentitis and abortion in captive bottlenose dolphins and

Revised May 15, 2014

blubber abscesses and meningoencephalitis in wild striped dolphins (Ewalt et al., 1994; Gonzalez et al., 2002). There are no *Brucella* species-specific gross lesions. To further resolve the possible contribution of these bacteria to impaired reproductive function and microscopic lesions in stranded killer whales. Attempted *Brucella* species-specific culture and isolation as well as molecular screening should be routinely undertaken with each stranded animal. Tissue samples should include multiple levels of the reproductive tract, brain, lung, spleen, lymph nodes and any gross abnormalities/lesions. To ensure optimum bacterial recovery, samples obtained at the time of necropsy should be shipped overnight on wet ice to a reference laboratory or frozen at -70 C and forwarded for evaluation as soon as possible (Table 2). *Brucella* serology may be considered. However, there are currently no validated serologic tests for killer whales (Gall et al., 2000). If indicated by histopathology, immunohistochemistry with monoclonal or polyclonal antibodies specific to *Brucella* may prove a valuable adjunct to confirm infection and assess the disease processes.

Zoonosis Warning: Marine *Brucella* sp. has infected a laboratory worker after occupational exposure (Brew et al., 1999) and neurobrucellosis with granuloma formation has been documented in two additional individuals with no known history of exposure (Sohn et al., 2003). The virulence of these strains to humans is currently unknown and appropriate public health and safety precautions at the time of necropsy are warranted. The precautions can include gloves, goggles, and a face mask when potentially aerosolizing tissue (such as when using a reciprocating saw).

CETACEAN MORBILLIVIRUS:

Porpoise and dolphin morbilliviruses are antigenically and genetically similar and are now generally considered strains of the same viral species, cetacean morbillivirus (Kennedy, 1998). This virus has caused large-scale epizootics in several odontocetes species (Van Bressemer et al., 1991; Duignan et al., 1995; Van Bressemer et al., 2001b). Detection of antibodies in a subadult killer whale recently captured in the northwest Pacific Ocean that succumbed to bacterial pneumonia (A. Mironova, per comm.) suggests that killer whales have been exposed to cetacean morbillivirus. Although no morbillivirus antibodies or gene sequences have yet been detected in stranded cetaceans in the temperate northeastern Pacific Ocean, this virus is likely endemic in multiple small cetaceans from around the world (Van Bressemer et al., 2001b). Because of the virulence of this virus and its potential to cause large-scale mortality in small populations, morbillivirus should be ruled out during all killer whale necropsies. Continued surveillance for antibodies to cetacean morbilliviruses in antemortem serum or post mortem heart blood samples by indirect enzyme linked immunosorbant assay (iELISA) or virus neutralization and attempted virus isolation are strongly recommended.

Cetacean morbillivirus is pantropic (infects a variety of cell types) and potential gross necropsy findings include skin ulcerations, stomatitis, pneumonia, and generalized signs of sepsis such as edema of internal organs and accumulation of serosanguinous fluid in the pleural and peritoneal cavities (Lipscomb et al., 1994). Gross lesions are not specific of morbillivirus infection but microscopic lesions are highly characteristic (Domingo et al., 2002). Microscopic lesions commonly seen with morbillivirus infection such as syncytia and acidophilic inclusions in cytoplasm and nuclei of epithelial cells can be widespread, focal, or obscured by severe necrosis caused by opportunistic bacterial and fungal infections. Microscopic examination and laboratory testing are essential to confirm morbillivirus infection. The tests used include immunohistochemistry, reverse transcriptase polymerase chain reaction (RT-PCR), and virus isolation on Vero cells or bovine fetal lung cells (Domingo et al., 1990; Van Bressemer et al.,

Revised May 15, 2014

1991; Barrett et al., 1993; Van Bressem et al., 1999; Saliki et al, 2002). Potential sequelae to cetacean morbillivirus infection include opportunistic bacterial and fungal infections, as well as toxoplasmosis (Lipscomb et al., 1994; Schulman and Lipscomb, 1999). These viruses are not likely a pathogen of concern for humans – but they represent a potentially significant health threat to killer whale populations.

INFLUENZA:

The detection of an influenza virus (H3N8) in the harbor seals stranded in the Northeastern United States in 2011 has renewed interest and concern regarding the potential risk of exposure and infection of other marine mammal species, terrestrial animals, birds and humans who may come into contact with carrier animals. To date, histopathology of stranded killer whales throughout the northeastern Pacific has not detected microscopic lesions consistent with infection by influenza and no virus has been identified by reverse transcriptase polymerase chain reaction in screened cases. However, the recent report of West Nile Virus in a display killer whale (St. Leger et al., 2012) suggests that orca may be susceptible to a broader array of viral pathogens than previously appreciated. Influenza from cetaceans could present a zoonotic concern and appropriate personal protective equipment (especially respiratory protection) should be utilized to reduce the likelihood of infection.

SALMONELLA:

Post mortem examination of an offshore neonate stranded in central California and an adult female killer whale in Hawaii did not reveal gross evidence of septicemia or localized bacterial infection. However, microscopic review of sampled tissues from the neonate disclosed inflammation of the umbilicus and multisystemic inflammation due to *Salmonella newport*. *Salmonella muenchen* was recovered from the adult female; the lack of associated inflammatory infiltrate within examined tissues suggested an asymptomatic carrier. There are over 2,200 recognized serovars of *Salmonella*. *Salmonella newport* is an emerging human health concern and is among the most common isolates from dairy cattle. It is important to note that these bacteria may directly infect people and can be carried on clothing, boots, or equipment to contaminate other areas. Thorough hand washing and disinfection of necropsy equipment should limit the risk of human and animal exposure.

APICOMPLEXANS:

The advent of molecular screening and gene sequencing has greatly enhanced our ability to detect a variety of disease agents, including tissue cyst forming protozoal parasites, such as those of the Apicomplexa. In marine mammals these include *Toxoplasma gondii*, *Sarcocystis neurona*, *Sarcocystis* spp, *Neospora caninum* and *Neospora* spp (Miller, 2008; Colgrove et al., 2010; Gibson et al., 2011). Representatives of this group of protozoa are of increasing concern due to potential land to sea transmission (Miller et al., 2004, etc.). Sexual reassortment has resulted in the emergence of hypervirulent clones. Although these pathogens have been implicated in sporadic mortality in near and off shore cetaceans, significant losses have been incurred historically in pinnipeds and otters. These parasites are associated with meningoencephalitis and transplacental infections or placentitis. Individual and dual parasite infections of *Toxoplasma gondii* and *Sarcocystis* spp. have been detected in a killer whale; however, the contribution of these parasites to strandings has not yet been resolved. Efforts are ongoing to screen stranded killer whales for possible infection. Subsequent genotyping is routinely undertaken to determine a potential source of exposure.

Revised May 15, 2014

PREVIOUSLY REPORTED PATHOGENS:

Reported pathogens from free-ranging or captive killer whales (Gaydos et al., 2004) are growing in number. Implementation of comprehensive necropsies and ancillary diagnostics has significantly contributed to this (Barbieri et al., 2013). Increasing knowledge of recognized pathogens and the potential contribution to clinical disease greatly enhances our understanding of killer whale morbidity and mortality. Please see Appendix II for reported infectious disease pathogens (Table 1) and endoparasites (Table 2) identified in killer whales.

Revised May 15, 2014

INTRODUCTION:

This protocol was first established in 2005 with goals to:

1. Provide guidelines for more comprehensive necropsies and disease testing to improve our knowledge about diseases of killer whales (*Orcinus* spp.)
2. Standardize screening to facilitate retrospective natural history and disease epidemiology studies.

In the past seven years, this protocol has greatly facilitated and enhanced killer whale examinations in the Northeast Pacific region, and we hope that this revised version will reflect scientific advancements in disease screening, heighten awareness of health concerns, and increase the number of complete postmortem standardized necropsies performed on killer whales.

The project was sponsored by the U.S. National Oceanic and Atmospheric Administration (NOAA Fisheries) in response to the limited information known about diseases of free-ranging killer whales. This information is critical to understanding how disease might impact the recovery of small declining killer whale populations, such as the southern resident killer whales. Historic estimates of this population were more than 200 whales until the mid- to late-1800's: the most recent census indicates 80 individuals. Since the start of killer whale photo-identification in 1974, the population has had several periods of growth and decline, including a 17% reduction (mean annual decline rate of 2.9%) between 1996 and 2001, prompting the petition and successful listing under the US Federal Endangered Species Act. Since 2001, the population grew to a high of 90 individuals in September 2006. The population has fluctuated. AS of September 2013, it totaled 81 individuals. The Recovery Plan for Southern Resident killer whales (NMFS 2008) recommends development of protocols for responding to stranded killer whales and investigations of dead killer whales to inform recovery, including necropsies following the 2005 protocol. This updated protocol contributes to implementation of these actions and will contribute to gathering important knowledge about the health of the whales and the threats they face.

A retrospective evaluation of stranded killer whales reported an average of seven to eight dead or beach cast killer whales around the world annually, making each killer whale stranding an important opportunity to learn more about the biology and health status of these animals (Barbieri et al., 2013). We hope killer whale researchers and responders around the world will use this protocol to increase information garnered from postmortem examinations.

Revised May 15, 2014

The objectives of this revised standardized necropsy and disease testing protocol are:

- Facilitate more comprehensive and systematic killer whale post mortem examinations
 - Prioritize morphometrics and tissue sampling when complete necropsies are not feasible or in cases of more advanced autolysis
 - Establish baseline patterns of morbidity and mortality in killer whales to facilitate retrospective evaluation of temporal and geographic differences in killer whale health
 - Ascertain the contribution of contaminant and heavy metal accumulation to killer whale health
 - Improve reporting of human interactions (blunt force and sharp injury trauma)
 - Introduce methods to investigate potential sonar or seismic related strandings
 - Develop protocols to conduct neonatal killer whale examinations
 - Enhance photo documentation of gross abnormalities or lesions
 - Identify resources for information regarding climatic and oceanographic factors, which may contribute to and facilitate back tracking of environmental factors associated with strandings
- Provide contact information and shipping addresses for priority samples required for diagnostics and long term research efforts
- List protocols and contacts in the event of a catastrophic oil or other noxious chemical spill
 - Through sampling requests, prioritize key organs to provide additional insights into the natural history and biology of wild stranded killer whales through sampling requests

A revised and expanded necropsy and sampling protocol is presented in the following text and relates specifically to North America. While the testing is focused on North American resources, the testing is universal and this protocol can be implemented globally. If resources are available, it is recommended that all killer whale necropsies follow this protocol. If your facility has appropriate tissue fixatives (formalin), a freezer and access to a microbiology laboratory, most of the listed tests should be readily accomplishable.

Revised May 15, 2014

EQUIPMENT CHECKLIST:

Note: This equipment checklist represents an ideal situation. Post- mortem exams can be completed with less equipment.

1. Morphometrics data sheet, gross necropsy form, human interaction form, and sample collection checklist
2. Standard necropsy instruments: multiple scalpel handles, scalpel blades, scissors, forceps, knives (3-10), knife sharpener, and 1-3 cutting boards, if possible in secure pack
3. Flensing knives (1-3) and hooks with appropriate sharpening tools, chain saw, axe, or reciprocating saw to cut through the cranium, chest or vertebrae. Hammers, chisels and handsaws
4. Retractors and gaff hooks of various sizes and shapes. Self-retaining retractors with one or two movable arms mounted on a slide bar are most useful
5. Sterile instruments, propane torch/gas burner, and searing spatula for sterile culture collection
6. Isopropol alcohol for flaming instruments
7. Flashlights and/or head lamps with extra batteries and light bulbs
8. Generator and flood lights with extra bulbs and fuel/gasoline (for night time exams)
9. 10% neutral buffered formalin (1- 10L) in wide-mouth spill-proof containers with screw-on lids. Extra-large, wide-mouth plastic storage bags are useful to place formalin containers in them along with absorbent cloth to prevent/limit spills
10. 4% buffered glutaraldehyde or suitable EM fixative (10-20 mL in multiple small vials)
11. 20% DMSO/saturated saline solution for genetic analysis (5mL) in a screw cap tube.
12. RNA-later for samples for future molecular analysis (5-20 mL split in multiple small vials)
13. Covered sealable containers (from vials to garbage cans) for sample collection, including ice chest, dry ice and if possible liquid nitrogen
14. Culture swabs, sterile urine cups, large screw-cap vials, glass slides
15. Serum tubes for fluid, blood and urine collection
16. Aluminum foil, Teflon bags, and plastic bags/Whirl-paks for freezing tissues
17. Paper for notes, labels (e.g. laundry tags with metal clips) and waterproof (Sharpie[®]) marking pens and pencils (for labeling specimens that will be immersed in fixatives).
18. Tape measure (metric), at least 20 meters long and small 12-15cm or 30 cm plastic rulers
19. Hoist/crane (for heavy organs), g/kg scales (for small tissues) to record organ weights
20. Coveralls, aprons, boots, gloves, caps, masks, protective eye and head gear
21. Accessible water supply with a large hose (for wash down and clean up)
22. Digital camera, GoPro camera, extra batteries with additional memory cards
23. Labels to identify digital images
24. First aid kit
25. Multiple plastic tarps, 10 meters.
26. Strong chain or rope, at least 20 meters.
27. Plastic tape and pylons to cordon off necropsy site.
28. Ice chest or cooler with ice to hold fresh samples
29. Garbage bags, dish soap, disinfectant, scrub brushes, paper towels for clean-up
30. Signs: WARNING – PUBLIC HEALTH HAZARD – DO NOT ENTER!

Revised May 15, 2014

LOGISTICS AND NECROPSY RECOMMENDATIONS

From a logistical perspective, advanced development of contingency plans will greatly facilitate identification, reporting, communication, recovery, necropsy and disposal of stranded animals. Key individuals for a killer whale stranding response should be identified and contact information provided to responsible government agencies, regional stranding coordinator, local aquarium facilities, and whale watching representatives and stranding networks. For example the West Coast Marine Mammal Stranding Network has a protocol for initial communications and considerations for killer whale stranding response, including identifying logistics for performing necropsies (Appendix XX).

If a killer whale strands in an inaccessible or remote site, or is identified floating in offshore areas, efforts to recover the animal and relocate by boat to a more accessible site are strongly recommended. If the animal can be re-floated, this may be accomplished by a large rope or chain secured around the peduncle or immediately behind the pectoral flippers and towed by a suitable vessel. To limit drag, the two front flippers should be tied together and maintained out of the water. To facilitate the post mortem examination, the animal should be positioned in lateral recumbency and secured ashore at high tide with exposure of the carcass attained with ebb flow. As tidal changes may limit the duration of the examination, use of heavy equipment (cranes, backhoes, hoists) and flatbed trucks to transport the animal to a more secure facility or a diagnostic laboratory may be considered. These animals may weigh up to 4000-6000 pounds and an appropriate vehicle should be employed. If the carcass is moved by truck, the vehicle should be weighed at a commercial weigh scale before and after transport to obtain the body mass of the carcass.

Should the animal require euthanasia, consultation with the regional stranding coordinator and a marine mammal veterinarian is required. Ante-mortem blood samples should be collected and appropriately stored for later clinical pathology (hematology and clinical chemistry), hormone analysis, serology, archiving, immune function and ancillary diagnostic and research investigations. With a fresh dead animal (code 2), post mortem blood may be collected from the tail flukes, dorsal fin, axillary artery, or heart. Even in animals with advanced states of decomposition, efforts to harvest tissues for histopathology, contaminants, genetics, parasitology, and molecular studies should be undertaken. Skeletal remains from animals in stages of severe decomposition (code 5) can also prove invaluable to ongoing studies in killer whale natural history.

SAFETY

Safety of the public and individuals involved with the post-mortem examination is a prime consideration. With any field necropsy, there is a risk of human exposure to potential zoonotic pathogens as well as interference with inappropriate public involvement. Use of face masks, protective eyewear and gloves is recommended. In areas with high public exposure, access should be restricted by pylons, tape or rope and use of law enforcement or fisheries officials may be warranted.

Revised May 15, 2014

NECROPSY TEAM ROLES

To facilitate the flow of the post mortem examination, team members should be identified and assigned to specific tasks before the necropsy is initiated. A lead pathologist or prosector should be designated and individuals appointed to complete data entry, process research samples (Appendix IV), label and record diagnostic material (Appendix I), document lesions and observations with photographs, liaise with the media or undertake additional tasks as necessary. Appropriate measurements (Appendix XXIII) should be recorded by designated team members and photographs of the dorsal fin and saddle patch, eye patches, and any other potential identifying features obtained before the necropsy is initiated (Appendix XXIV). A digital still camera or GoPro[®] should be used to record details of the post-mortem examination.

Consider forming two teams to increase data and tissue collections. One team can collect morphometrics while another team collects external photos and documents external lesions. If you have 2 lead prosectors, there can be a head and abdomen team until they meet in the middle.

Consider organizing a single sampling station just away from the necropsy. ALL tissues are harvested and then sent to sampling table for subsampling. The data sheets and sampling team leader are stationed there making sure ALL protocols are filled. In this way a single block of liver harvested from the whale is delivered to the sampling table and is subsampled to fill all protocols and requests. Specific sample vials (usually fluids) are brought to the carcass to be filled before the organs are excised.

EXTERNAL EXAM AND PRE-DISSECTION SAMPLING

In the case of live strandings, ante-mortem blood samples should be collected and appropriately stored for later clinical pathology (hematology and clinical chemistry), hormone analysis, serology, archiving, immune function and ancillary diagnostic and research investigations. With a fresh dead animal, post mortem blood may be collected from the tail flukes, dorsal fin, axillary artery, or heart. Even in animals with advanced states of decomposition, efforts to harvest tissues for histopathology, contaminants, genetics, parasitology, and molecular studies may be undertaken. Skeletal remains from animals in stages of severe decomposition can also prove invaluable to ongoing studies in killer whale natural history.

External examination and photo documentation of the eyes, mouth, blowhole, skin, mammary glands, genital slits and anus should be performed prior to cutting the animal. The dorsal fin and area immediately around the base of the fin should be examined for evidence of any prior attachment of LIMPET satellite tags (Andrews et al. 2009). Signs of human interaction should be recorded (Appendix XXI). Once the external examination and tissue sampling (swabs, cytology and tissues) has been completed and lesions documented (i.e. by photography and description), proceed with the dissection.

Revised May 15, 2014

DECOMPOSITION TABLE:

Code 1	Live stranded	Self-evident
Code 2	Fresh dead	Skin firm, organs fresh
Code 3	Moderate decomposition	Body swelling, skin deterioration, often advanced scavenging, organs red and soft but discernible
Code 4	Advanced decomposition	Organs difficult to clearly discern, skin sloughing, often swollen and expelled GI tract or repro organs
Code 5	Severe decomposition	Skeletal remains with associated soft tissue remnants

The post mortem approach will be determined to some extent on the animal's position, accessibility, lesions and other factors. Although cosmetic necropsy may be requested to preserve the skeleton intact, this procedure should not compromise or impede appropriate tissue collection.

IMAGING CONSIDERATIONS

Prior to the dissection, ancillary imaging such as radiographs, Computed Tomography (CT) examination, and Magnetic Resonance Imaging (MRI) should be performed if feasible (Appendix XII). In general, code 2 specimens weighing less than 225 kg (500 pounds) are candidates for whole body imaging. Animals up to 1000 kg (2200 pounds) are candidates for partial (head, spine, flipper) body imaging. Decomposition will lead to gas production associated with bacterial putrefaction. However, even carcasses with advanced decomposition are good candidates for CT to evaluate skeletal condition and document complex bone changes. CT imaging of carcasses or heads is the preferred manner of examining for bones fractures, barotrauma and bullets. **If gunshot is a concern, MRI evaluation is strongly contraindicated.** Consultation with local radiology specialty veterinary clinics or human hospitals prior to imaging studies is recommended.

If the animal is too large for standard imaging, the head can be removed following morphometrics and the external examination. The head can then be transported quickly to a local facility for imaging. NOTE: do not freeze the head without first harvesting the brain and eyes.

DISSECTION

With the animal in lateral recumbency (laying on its side), a curvilinear full blubber thickness incision may be made from the caudal limit of the anus, along the dorsolateral aspect of the abdominal and thoracic cavities, terminating at the level of the rostral limit of the mandibular ramus. Perpendicular cuts from the dorsum to the mid-abdominal region will facilitate reflection and removal of the skin and blubber and exposure of the underlying tissues. The lateral skin and blubber can then be reflected with metal retractors from the underlying musculature *en masse*, or divided into suitable 0.5-1.0 m portions and removed. Excised tissues should be removed from the dissection area and placed on a plastic tarp to facilitate clean up and limit environmental contamination. Tissue lists for diagnostic and research evaluation are listed in appendices (I and II).

The abdominal musculature may be incised along the costochondral arch and dorsal limit of the abdominal cavity, then reflected laterally or ventrally to expose the abdominal viscera. The

Revised May 15, 2014

diaphragm should be assessed, and if intact, incised and deflated to exclude pneumothorax. If a cosmetic post-mortem is requested, the ribs may be detached at the costosternal junction and reflected, or alternatively a chain or reciprocating saw may be employed to remove the thoracic wall. It is important that protective eye wear or face shields be employed by the operator and prosectors. The tongue may be exteriorized by incision of the blubber and skeletal musculature along the entire length of the medial aspect of the mandibles and then reflected ventrally. If feasible, the lung, heart, larynx, trachea and esophagus, and tongue (pluck) should be removed to a tarp for thorough evaluation. With larger animals, dissection of thoracic viscera *in situ* may be warranted. The head may be detached by dissection of the atlanto-occipital articulation and the skin overlying the dorsolateral aspect of the nape and cranium removed. This exposure will facilitate removal of the dorsal aspect of the skull by either chain or reciprocating saw and exposure of the brain. It is important to evaluate the entire length of the vertebral column to assess possible vertebral fractures or subluxations associated with boat strikes or other trauma; a representative portion of spinal cord should be recovered from the cervical, mid- thoracic, thoracolumbar and lumbar regions.

Due to the importance of the reproductive organs in disease screening and assessment of reproductive status, recover and completely excise the reproductive tract for evaluation. As with other organ systems, decomposition and physical characteristics will determine the best sampling plan for this system.

The mesenteric stalk should then be identified, evaluated for lesions, then transected to facilitate removal and evaluation of the abdominal viscera. The viscera should be placed on a separate tarp to that of the thoracic contents to limit cross contamination. The entire length of bowel should be detached from the mesenteric attachment and opened for visual inspection by incising along one side of the mesenteric border. The stomach should then be incised along the greater curvature and the gastric contents recovered and appropriately packaged and labeled. Samples will be partitioned for a variety of ancillary investigations (Appendix I). The remaining internal viscera should be evaluated by routine or conventional diagnostic protocols and appropriate research and diagnostic samples harvested and labeled.

With suspect sonar related strandings, arrangements should be made for CT scan of the entire head or ears and close evaluation of the larynx should be undertaken for evidence of submucosal hemorrhage. If the CT is not conducted prior to the necropsy, the head and ears can be collected and scanned at a later time. EARs can also be extracted and fixed for analysis (Appendix XV). Samples of peribullar adipose tissue should be collected into 10% neutral buffered formalin for histopathologic evaluation. Note: decomposition to code 3 can produce intravascular and parenchymal gas bubbles. These are distinguished from bubbles associated with acoustic trauma based on tissue freshness and associated lesions such as pulmonary and peribullar fat hemorrhage and damage to the ear bones. Appendix XVI provide guidance for gas bubble sampling.

SKELETAL EXAMINATION AND PREPARATION CONSIDERATIONS

Postmortem investigations should involve review of both soft and hard tissues. Examination of bones for malformations, degenerative changes, fractures, inflammation and masses is critical to a thorough understanding of the health issues affecting an individual killer whale. Bones are most commonly evaluated through diagnostic imaging (radiographs and CT exams) and at the gross exam with bone exposure by flensing. Due to the large size of killer whales and the

Revised May 15, 2014

difficulty in soft tissue removal, a thorough examination typically requires either maceration of tissue, or soft tissue removal via beetles or decomposition through burying. This step is often critical to evaluate the skeleton and obtain a clear diagnosis.

Bone fissures, cracks and fractures can occur ante- or postmortem. Because of this, presence or absence of associated hemorrhage, reactive change along bone margins or muscle damage in the vicinity of breaks should be specifically noted. Boat strike can occur post-mortem. Bone scrapes likewise, can occur as the direct result of trauma or on exposed bones tossed against rocks and sand postmortem. Again, ancillary findings help to determine the significance. Lastly, fracture patterning and the morphology of fractured edges, e.g. presence of blood clots may substantially contribute to the diagnosis of ante-mortem trauma.

Cleaned skeletons also have value to museums, researchers, and educational institutions. Once the examination is completed, please contact Dr. Brad Hanson or Dr. John Ford (see Appendix IIB) for options for long-term curation.

APPENDICES, CONTACTS, AUTHORIZATION AND PERMITS

An equipment list is attached (page 10) and diagnostic, as well as research, tissue lists are provided in Appendices I and II. With oil spill and forensic cases, chain of custody forms should be appropriately completed and forwarded with tissue samples (Appendix XIII). When tissues samples are forwarded to a reference lab or contact individual outside the country of origin, appropriate authorization and permits from the lead agency such as US Fish and Wildlife (for CITES) and NOAA/NMFS (for MMPA) are required (see Appendix V).

ACKNOWLEDGMENTS

We wish to thank the numerous people who contributed content to this document. We offer special thanks to stranding coordinators, stranding responders, and First Nations peoples who have made and continue to make the enactment of these investigations a reality. Funding for this project was provided by the U.S. Department of Commerce National Oceanic & Atmospheric Administration. In-kind support also was provided by the SeaDoc Society, a program of the Wildlife Health Center, School of Veterinary Medicine, University of California, Davis, Sea World Parks and Entertainment, and the Animal Health Center, British Columbia Ministry of Agriculture. Specific thanks are due to Lynne Barre, Kathy Burek, John Ford, Sal Frasca, Justin Greenman, Michael Grigg, Frances Gulland, Brad Hanson, Aleria Jensen, Linda Lowenstine, Bill McClelland, Michael Moore, Erika Nilson, Hendrick Nollens, Ann Pabst, Lisa Spavin, Justin Viezbicke, and Gina Ylitalo for reviewing this document prior to the 2014 release. Killer whale drawings on gross pathology recording form by Lee Harrison/©Free Morgan Foundation.

LITERATURE CITED:

- Barbieri, M. M., S. A. Raverty, M. B. Hanson, and S. Venn-Watson, J. K. B. Ford and J. K. Gaydos. 2013. Spatial and temporal analysis of killer whale strandings in the North Pacific Ocean and the benefits of a coordinated stranding response protocol. *Marine Mammal Science* DOI: 10.1111/mms.12044, 15 pages.
- Barrett, T., I. K. G., L. Mamaev, L. Goatley, M-F. Van Bresseem, and A.D.M.E. Osterhaus. 1993.

Revised May 15, 2014

- Dolphin and porpoise morbilliviruses are genetically distinct to phocine distemper virus. *Virology* 200: 10101012.
- Bossart, G. D., and E. Eimstad. 1988. *Erysipelothrix vesicular glossitis* in a killer whale (*Orcinus orca*). *Journal of Zoo Animal Medicine* 19:42-47.
- Bossart, G. D., T. A. Brawner, C. Cabal, M. Kuhns, E. A. Eimstad, J. Caron, M. Trimm, and P. Bradley. 1990. Hepatitis B-like infection in a Pacific white-sided dolphin. *Journal of the American Veterinary Medical Association* 196:127-130.
- Bossart, G. D., C. Cray, J. L. Solorazano, S. J. Decker, L. H. Cornell, and N. H. Altman. 1996. Cutaneous papillomaviral-like papillomatosis in a killer whale (*Orcinus orca*). *Marine Mammal Science* 12:274-281
- Brew, S.D., L. L. Perrett, J. A. Stack, A. P. MacMillan, and N.J. Staunton. 1999. Human exposure to *Brucella* recovered from a sea mammal. *Veterinary Record* 144:483
- Cloeckaert A., M. Grayon, O. Grepinet, and K.S. Boumedine. 2003. Classification of *Brucella* spp. Isolated from marine mammals by DNA polymorphism at the omp-2 locus. *Microbes and Infections* 5(7):593-602
- Dailey, M. D., 2001. Parasitic Diseases. *In* CRC Handbook of Marine Mammal Medicine, 2nd Edition L. A. Dierauf and F. M. D. Gulland (eds.). CRC Press, Boca Raton, Florida. Pp. 357-379.
- Daily, M. D. and R. L. Brownell. 1972. A checklist of marine mammal parasites. *In* Mammals of the Sea, Biology and Medicine. S. Ridgway (ed.). Charles C. Thompson, Springfield, Illinois. Pp. 528-589.
- Domingo, M, L. Ferrer, M. Pumarola, A. Marco, J. Plana, S. Kennedy, M. McAlisky, and B.K. Rima. 1990. Morbillivirus in dolphins. *Nature* 348:21.
- Domingo, M., Kennedy, S. and M-F. Van Bresseem. 2002. Marine Mammal Mass Mortalities. *In* Marine Mammals Biology and Conservation P.J.G.H. Evans and A.J. Raga (eds.). Kluwer Academic / Plenum Publishers, New York, Pp. 425-456.
- Duignan, P. J., C. House, J. R. Geraci, N. Duffy, B. K. Rima, M. T. Walsh, G. Early, D. J. St Aubin, S. Sadove, H. Koopman, and H. Rhinehart. 1995. Morbillivirus infection in cetaceans of the western Atlantic. *Veterinary Microbiology*. 44:241-249.
- Dunn, J. L., J. D. Buck, and T. R. Robeck. 2001. Bacterial Diseases of Cetaceans and Pinnipeds. *In* CRC Handbook of Marine Mammal Medicine, 2nd Edition. L. A. Dierauf and F. M. D. Gulland (eds.). CRC Press, Boca Raton, FL. Pp. 309-335.
- Ewalt, D. R., D. R. Payeur, B. M. Martin, D. R. Cummins, and W.G. Miller. 1994. Characteristics of a *Brucella* species isolated from bottlenose dolphins (*Tursiops truncatus*). *Journal of Veterinary Diagnostic Investigation* 6:448-452.
- Ford, J. K. B., G. M. Ellis, K. C. Balcomb. 2000. *Killer whales: The natural history and genealogy of Orcinus orca in British Columbia and Washington*. University of British Columbia Press, Vancouver.
- Foster, G., K. L. Jahans, R. J. Reid, and H. M. Ross. 1996. Isolation of *Brucella* species from cetaceans, seals and an otter. *Veterinary Record*. 138:583-586.
- Gall, D, K. Nielsen, L. Forbes, D. Davis, P. Elzer, S. Olsen, S. Balsevicius, L. Kelly, P. Smith, S. Tan, and D. Joly. 2000. Validation of the fluorescent polarization assay and comparison to other serologic assays for the detection of serum antibodies to *Brucella abortus* in Bison. *Journal of Wildlife Diseases*. 36:469-476.
- Gaydos, J.K., K. C. Balcomb, III, R. Osborne, and L Dierauf. 2004. Evaluating potential infectious disease threats for southern resident killer whales, *Orcinus orca*: a model for endangered species. *Biological Conservation*. 117:253-262.
- Geraci, J. R, J. Harwood, and V. J. Lounsbury. 1999. Marine mammal die-offs. Causes,

Revised May 15, 2014

- investigations and issues. In Conservation and Management of Marine Mammals. J. R. Twiss and R. R. Reeves (eds.). Smithsonian Institution Press, Washington, D.C. Pp. 367-396.
- Gibson, D. I. and R. A. Bray. 1997. *Oschmarinella albamarina* (Treschev, 1968) n. comb., a liver fluke from the killer whale *Orcinus orca* (L.) off the British coast. *Systematic Parasitology*. 36:39-45.
- Gibson, D.I., E. A. Harris, R. A. Bray, P. D. Jepson, T. Kuiken, J. R. Baker, and V.R. Simpson. 1998. A survey of the helminth parasites of cetaceans stranded on the coast of England and Wales during the period 1990-1994. *Journal of Zoology, London*. 244:563-574.
- Gonzalez L, I. A. Patterson, R. J. Reid, G. Foster, M. Barberan, J. M. Blasco, S. Kennedy, F. E. Howie, J. Godfroid, A. P. MacMillan, A. Schock, and D. Buxton. 2002. Chronic meningoencephalitis associated with *Brucella* sp. infection in live-stranded striped dolphins (*Stenella coeruleoalba*). *Journal of Comparative Pathology*. 126:147-152.
- Greenwood, A. G., and D. C. Taylor. 1985. Captive Killer Whales in Europe. *Aquatic Mammals* 1:10-12.
- Gulland, F. M., L. A. Dierauf, and T. K. Rowles. 2001. Marine mammal stranding networks. In *CRC Handbook of Marine Mammal Medicine 2nd Edition*. L. A. Dierauf and F. M. Gulland (eds.). CRC Press, New York, New York. Pp. 45-67.
- Harms, C.A., W. A. McLellan, M. J. Moore, S. G. Barco, E. O. Clarke EO, V. G. Thayer and T. K. Rowles. 2014. Low residue euthanasia of stranded mysticetes. *Journal of Wildlife Diseases* 50:63-73.
- Heptner, V.G., K. K. Chapskii, V. A. Arsen'ev., and V. E. Sokolov. 1976. Mammals of the Soviet Union. Volume II, part 3. Pinnipedia and Odontoceti. Vysshaya Shkola Publishers, Moscow, Soviet Union. (English translation, 1996, Science Publishers, Lebanon, New Hampshire).
- Hicks, C. L., R. Kinoshita, and P. W. Ladds. 2000. Pathology of meliodosis in captive marine mammals. *Australian Veterinary Journal* 78:193-195.
- Jepson, P. D., S. Brew, A. P. MacMillan, J. R. Baker, J. Barnett, J. K. Kirkwood, T. Kuiken, I. R. Robinson, and V. R. Simpson. 1997. Antibodies to *Brucella* in marine mammals around the coast of England and Wales. *The Veterinary Record* 141:513-515.
- Kennedy S. Morbillivirus infection in aquatic mammals. 1998. *Journal of Comparative Pathology*. 119:201-225.
- Lipscomb T.P., Kennedy S., Moffett D., and B.K. Ford. 1994. Morbilliviral disease in an Atlantic bottlenose dolphin (*Tursiops truncatus*) from the Gulf of Mexico. *Journal of Wildlife Diseases*. 30:572-576.
- Nielsen, O., R. E. Stewart, K. Nielsen, L. Measures, and P. Duignan. 2001. Serologic survey of *Brucella* spp. antibodies in some marine mammals of North America. *Journal of Wildlife Diseases*. 37:89-100.
- NMFS. 2008. Recovery plan for Southern Resident killer whales (*Orcinus orca*). National Marine Fisheries Service, Northwest Region, Seattle, Washington.
- Raverty, S., K. Nielsen, O. Nielsen, B. Hanson, and J. K. Gaydos. 2004. Detection of *Brucella* spp. antibodies in post mortem heart blood and antemortem serum of killer whales (*Orcinus orca*) in the Pacific Northwest. *Proceedings of the 35th International Association for Aquatic Medicine Conference*, Galveston, Texas. Pp 114-115.
- Reidarson, T. H., J. F. McBain, L. M. Dalton, and M. G. Rinaldi. 1999. Diagnosis and treatment of fungal infections in marine mammals. In *Zoo and Wild Animal Medicine Current Therapy 4th Edition*. M. E. Fowler and R. E Miller (eds.). W.B. Saunders Company, Philadelphia, Pennsylvania. Pp. 478-485.

Revised May 15, 2014

- Ridgway, S.H. 1979. Reported causes of death of captive killer whales (*Orcinus orca*). *Journal of Wildlife Diseases* 15: 99-104. Ross, H.M., K. L. Jahans, A. P. MacMillian, R. J. Reid, P. M. Thompson, and G. Foster. 1996. *Brucella* species infection in North Sea seal and cetacean populations. *Veterinary Record* 138:647-648.
- Rowles, T. K., F. Van Dolah, and A. A. Hohn. 2001. Gross necropsy and specimen collection protocols. In *CRC Handbook of Marine Mammal Medicine 2nd Edition*. L. A. Dierauf and F. M. Gulland (eds.). CRC Press, New York, New York. Pp. 449-470.
- Saliki J. T., E. J. Cooper, and J. P. Gustavson. 2002. Emerging morbillivirus infections of marine mammals: development of two diagnostic approaches. *Annals of the New York Academy of Science*. 969:51-59.
- Schulman, Y.S and T. Lipscomb. 1999. Dermatitis and invasive ciliated protozoa in dolphins that died during the 1987-1988 Atlantic bottlenose dolphin morbillivirus epizootic. *Veterinary Pathology* 36:171-174.
- Sneizek, J.H., D. W. Coates, and E.B. Small. 1995. *Kyaroikeus cetarius* n.g., n. sp., a parasitic ciliate from the respiratory tract of odontocete cetacea. *Journal of Eukaryotic Microbiology*. 42:260-268.
- Sohn, A.H., W. S. Probert, C. A. Glaser, N. Gupta, A. W. Bollen, J. D. Wong, E. M. Grace, and W.C. McDonald. 2003. Human neurobrucellosis with intracerebral granuloma caused by a marine mammal *Brucella* spp. *Emerging Infectious Diseases*. 9(4): 485-8.
- St. Leger, J.A., G. Wu, M. Anderson, L. Dalton, E. Nilson, and D. Wang. West Nile Virus Infection in Killer Whale, Texas, USA, 2007. *Emerging Infectious Diseases*. 17:1531-1533.
- Sweeney, J. C., G. Miyaki, P. M. Vainik, and R. H. Conklin. 1976. Systemic mycoses in marine mammals. *Journal of the American Veterinary Medical Association* 169:946-948.
- US Federal Register. 2005. Endangered and threatened wildlife and plants: Endangered status for southern resident killer whales. 70(222):69903-69912.
- Van Bresseem, M. F., K. Van Waerebeek, and J. A. Raga. 1999. A review of virus infections of cetaceans and the potential impact of morbilliviruses, poxviruses, and papillomaviruses on host population dynamics. *Diseases of Aquatic Organisms* 38:53-65.
- Van Bresseem, M. F., K. Van Waerebeek, J. A. Raga, J. Godfroid, S. D. Brew, and A. P. MacMillan, 2001a. Serological evidence of *Brucella* species infection in odontocetes from the south Pacific and the Mediterranean. *Veterinary Record*, 148:657-661.
- Van Bresseem, M. F., K. Van Waerebeek, P. Jepson, J. A. Raga, P. J. Duignan, O. Nielsen, A. P. Di Benedetto, S. Siciliano, R. Remos, W. Kant, V. Peddemors, R. Kinoshita, P. S. Ross, A. Lopez-Fernandez, K. Evans, E. Crespo, and T Barrett. 2001b. An insight into the epidemiology of dolphin morbillivirus worldwide. *Veterinary Microbiology* 81:287-304.
- Van Bresseem, M.-F., I. K. G. Visser, M. W. G. Van De Bildt, J. S. Teppema, J. A. Raga, and A. D. M. E. Osterhaus. 1991. Morbillivirus infection in Mediterranean striped dolphins (*Stenella coeruleoalba*). *Veterinary Record*. 129:471-472.
- Young, S. J., R. L. Lewis, J. K. B Ford, and G. Ellis. 1997. First case report – mortality of a wild resident killer whale (*Orcinus orca*) from *Erysiplothrix rhusopathiae*. *Proceedings of the International Association for Aquatic Animal Medicine*, Baltimore Maryland, pp. 64-68.

Revised May 15, 2014

KILLER WHALE NECROPSY PROTOCOL COMPREHENSIVE KILLER WHALE TISSUE SAMPLE CHECKLIST

Tissue	Test	Sample	Preservation
Blowhole	Bacteriology	Swab	Transport media
Genital slit	Bacteriology	Swab	Culture swab
Vagina	Bacteriology	Swab	Culture swab
Uterus	Bacteriology	Swab	Culture swab
Ovary	Bacteriology	Swab	Culture swab
Penis/testes	Bacteriology	Swab	Culture swab
Lung	Bacteriology	Swab	Culture swab
Trachea	Bacteriology	Swab	Culture swab
Lymph node, multiple sites	Bacteriology	Swab	Culture swab
Thymus	Bacteriology	1-2 cm ³ tissue sample	Plastic bag and freeze
Spleen	Bacteriology	1-2 cm ³ tissue sample	Plastic bag and freeze
Heart	Bacteriology	5 ml post mortem heart blood	Red topped tube or plastic bag and chill
Stomach	Bacteriology	Stomach	Culture swab
Small intestine, ileum and jejunum	Bacteriology	Swab	Culture swab
Colon	Bacteriology	Swab	Culture swab
Conjunctiva	Bacteriology	Swab	Culture swab
Teeth	Aging	1-2 intact	Plastic bag
Dorsal fin	Anatomy	Excise intact	Seal in plastic and freeze
Head	Anatomy	Intact	Plastic bag and freeze
Thymus	Archive	Multiple, 1-2 cm portions	Plastic bag and freeze
Spleen	Archive	Multiple, 1-2 cm ³ portions	Plastic bag and freeze
Thyroid gland	Archive	Multiple, 1-2 cm ³ portions	Plastic bag and freeze
Parathyroid gland	Archive	Multiple, 1-2 cm ³ portions	Plastic bag and freeze
Brain - cerebrum	Archive	Multiple, 1-2 cm ³ portions	Plastic bag and freeze
Brain - cerebellum	Archive	Multiple, 1-2 cm ³ portions	Plastic bag and freeze

Revised May 15, 2014

Brain - brainstem	Archive	Multiple, 1-2 cm ³ portions	Plastic bag and freeze
Spinal cord (thoracic)	Archive	Multiple, 1-2 cm ³ portions	Plastic bag and freeze
Liver	Archive	Multiple, 1-2 cm ³ portions	Plastic bag and freeze
Kidney	Archive	Multiple, 1-2 cm ³ portions	Plastic bag and freeze
Adrenals	Archive	Multiple, 1-2 cm ³ portions	Plastic bag and freeze
Ureter	Archive	Multiple, 1-2 cm ³ portions	Plastic bag and freeze
Urinary bladder	Archive	5-10 ml urine and bladder wall	Plastic bag and freeze
Rib/Bone marrow	Archive	1-2 cm ³	Plastic bag and freeze
Diaphragm	Archive	2x2 cm	Plastic bag and freeze
Milk	Archive	Aspirate	Plastic bag and freeze
Uterus	Archive	Tissue samples	Plastic bag and freeze
Ovary	Archive	If possible, retain corpora intact	Histopathology
Oviduct	Archive	Tissue samples	Plastic bag and freeze
Trachea	Archive	Tissue samples	Plastic bag and freeze
Lymph node, multiple sites	Archive	Whole or partial nodes	Plastic bag and freeze
Pituitary gland	Archive	Half	Plastic bag and freeze
Heart	Archive	Tissue samples	Plastic bag and freeze
Bile	Archive	5-10 ml	Plastic bag and freeze
Pancreas	Archive	5-10 gm	Plastic bag - freeze
Small intestine, multiple levels	Archive	Ligated bowel	Plastic bag and freeze
Colon	Archive	Ligated bowel	Plastic bag and freeze
Skeletal muscle	Archive	5x5 cm	Plastic bag and freeze
Oropharynx/tonsil	Bacteriology	Swab	Culture swab
Umbilicus	Bacteriology	Swab	Culture swab
Mammary gland	Bacteriology	Swab	Culture swab
Joint fluid	Bacteriology	Swab	Culture swab

Revised May 15, 2014

Urinary bladder	Biotoxin assay, cytology/culture	5-10 ml	Sterile plastic bag and freeze
Stomach	Biotoxin assay, prey selection	Entire or portion of ingesta	Place in plastic bag and freeze
Eye	Clinical chemistry	Aspirate 3-5 ml of vitreous	Red top tube and chill
Small intestine, ileum and jejunum	Contents	Ligated bowel	Place in plastic bag and chill
Ears	CT scan	Intact	Plastic bag and freeze
Blowhole	Cytology	Scraping	Air dry and stain
Mammary gland	Cytology	Aspirate	Plastic bag and chill
Joint fluid	Cytology	5 ml	Red top tube
Rib/Bone marrow	Cytology	Smear	Air fix/alcohol
Pericardial fluid	Cytology and serology	10 ml	Red top tube or plastic bag and freeze
Conjunctiva	Electron microscopy	Dry swab	Place in Whirl-pak® bag and chill
Skin	Genetics	1 cm ³	DMSO or freeze
Skin, multiple sites, including lesioned and non-lesioned	Histopathology	See Guidelines (*)	Formalin
Oral mucosa	Histopathology	See Guidelines (*)	Formalin
Oropharynx	Histopathology	See Guidelines (*)	Formalin
Blowhole and air sacs	Histopathology	See Guidelines (*)	Formalin
Tonsil	Histopathology	See Guidelines (*)	Formalin
Conjunctiva	Histopathology	See Guidelines (*)	Formalin
Umbilicus	Histopathology	See Guidelines (*)	Formalin
Mammary gland	Histopathology	See Guidelines (*)	Formalin
Tongue	Histopathology	See Guidelines (*)	Formalin
Eye	Histopathology	Intact, inject with 1-2 cc of formalin	Formalin
Genital slit	Histopathology	See Guidelines (*)	Formalin
Vagina	Histopathology	See Guidelines (*)	Formalin
Uterus	Histopathology	1x2 cm	Formalin
Ovary	Histopathology	See Guidelines (*)	Formalin
Oviduct	Histopathology	See Guidelines (*)	Formalin
Penis/testes	Histopathology	See Guidelines (*)	Formalin
Accessory sex glands	Histopathology	See Guidelines (*)	Formalin
Lung	Histopathology	See Guidelines (*)	Formalin
Trachea	Histopathology	See Guidelines (*)	Formalin
Lymph node, multiple sites	Histopathology	See Guidelines (*)	Formalin
Thymus	Histopathology	See Guidelines (*)	Formalin

Revised May 15, 2014

Spleen	Histopathology	See Guidelines (*)	Formalin
Thyroid gland	Histopathology	See Guidelines (*)	Formalin
Parathyroid gland	Histopathology	See Guidelines (*)	Formalin
Brain - cerebrum	Histopathology	See Guidelines (*)	Formalin
Brain - cerebellum	Histopathology	See Guidelines (*)	Formalin
Brain – brainstem, pons, medulla, colliculus	Histopathology	See Guidelines (*)	Formalin
Ears	Histopathology	Peribullar fat	Formalin
Pituitary gland	Histopathology	Half	Formalin
Spinal cord (thoracic)	Histopathology	See Guidelines (*)	Formalin
Brachial plexus	Histopathology	1-2 cm ³	Formalin
Heart, interventricular septa, ventricles, atria, papillary muscle and valve	Histopathology	See Guidelines (*)	Formalin
Aorta and vena cava, multiple levels	Histopathology	Aorta and vena cava, multiple levels	Histopathology
Liver	Histopathology	See Guidelines (*)	Formalin
Pancreas	Histopathology	See Guidelines (*)	Formalin
Stomach	Histopathology	See Guidelines (*)	Formalin
Small intestine, ileum and jejunum	Histopathology	See Guidelines (*)	Formalin
Colon	Histopathology	See Guidelines (*)	Formalin
Kidney	Histopathology	See Guidelines (*)	Formalin
Adrenals	Histopathology	See Guidelines (*)	Formalin
Ureter	Histopathology	See Guidelines (*)	Formalin
Urinary bladder	Histopathology	See Guidelines (*)	Formalin
Skeletal muscle	Histopathology	See Guidelines (*)	Formalin
Rib/Bone marrow	Histopathology	See Guidelines (*)	Formalin
Peripheral nerve	Histopathology	See Guidelines (*)	Formalin
Diaphragm	Histopathology	See Guidelines (*)	Formalin
Blubber	Lipid analysis	10 cm ³	Aluminum foil and freeze
Oropharynx	Molecular studies	Dry swab	Place in plastic bag and chill
Blowhole	Molecular studies	Dry swab	Place in plastic bag and chill
Tonsil	Molecular studies	1-2 cm ³	Plastic bag and freeze
Conjunctiva	Molecular studies	Swab	Place in whirlpak bag and chill
Genital slit	Molecular studies	Dry swab	Place in plastic bag and chill
Vagina	Molecular studies	Dry swab	Place in plastic bag and chill

Revised May 15, 2014

Uterus	Molecular studies	Dry swab	Place in plastic bag and chill
Ovary	Molecular studies	Dry swab or 1-2 cm tissue sample	Place in plastic bag and chill
Penis/testes	Molecular studies	Dry swab	Place in plastic bag and chill
Lung	Molecular studies	1x1 cm tissue	Place in plastic bag and chill
Lymph node, multiple sites	Molecular studies	Dry swab	Place in plastic bag and chill
Thymus	Molecular studies	1-2 cm ³ tissue sample	Place in plastic bag and chill
Spleen	Molecular studies	1-2 cm ³ tissue sample	Place in plastic bag and chill
Water sample	Molecular studies	10 ml	Plastic bag and freeze
Mandible	Morphometric study	Intact	Plastic bag and freeze
Blowhole	Mycology	Swab	Transport media
Genital slit	Mycology	Swab	Culture swab
Vagina	Mycology	Swab	Culture swab
Uterus	Mycology	Swab	Culture swab
Penis/testes	Mycology	Swab	Culture swab
Lung	Mycology	Swab	Culture swab
Lymph node, multiple sites	Mycology	Swab	Culture swab
Small intestine	Mycology	Swab	Culture swab
Colon	Mycology	Swab	Culture swab
Blowhole	<i>Mycoplasma</i> culture	Swab	Culture swab
Lung	<i>Mycoplasma</i> culture	Swab	Culture swab
Genital slit/Urogenital canal	<i>Mycoplasma</i> culture	Swab	Culture swab
Middle ear	<i>Mycoplasma</i> culture	Swab	Culture swab
Blowhole	Parasitology	Swab	Preserve in Bouin's
Tongue	Parasitology	3x3 cm	Plastic bag and freeze
Stomach	Parasitology	Ingesta	Plastic bag and chill
Colon	Salmonella culture	Swab	Culture swab
Mandible	Sonar related injury	Internal mandibular fat	Histopathology
Pericardium	Tissue culture	Pericardium	Tissue culture

Revised May 15, 2014

Blubber	Toxicology Contaminant	3x3 cm	Aluminum foil and freeze
Liver	Toxicology Contaminant	3x3 cm	Aluminum foil and freeze
Kidney	Toxicology Contaminant	3x3 cm	Aluminum foil and freeze
Bile	Toxicology Contaminant	1-2 mL	Glass vial and freeze
Feces	Toxicology Contaminant	2- 5g	Glass jar and freeze
Kidney	Trace mineral analysis	5x5 cm	Plastic bag and freeze
Liver	Trace mineral and vitamin analysis	5x5 cm	Plastic bag and freeze
Urinary bladder	Urinalysis	5-10 ml	Red top tube
Tonsil	Virus Isolation	5 gm	Plastic bag and chill or freeze
Lung	Virus Isolation	5 gm	Plastic bag and chill or freeze
Lymph node, multiple sites	Virus Isolation	5 gm	Plastic bag and chill or freeze
Spleen	Virus Isolation	5 gm	Plastic bag and chill or freeze
Brain - cerebrum	Virus Isolation	5 gm	Plastic bag and chill or freeze
Kidney	Virus Isolation	5 gm	Plastic bag and chill or freeze
Thyroid gland	Weight	Intact gland	Fresh
Pituitary gland	Weight	Intact	Fresh
Kidney	Weights	Intact	Fresh

Revised May 15, 2014

APPENDIX I: Sample Priorities based on Tissue Condition

Circumstances associated with killer whale stranding and resources available at the time of post mortem examination will vary considerably and some flexibility and discretion must be afforded to the necropsy team. In those situations where autolysis, location, equipment, personnel or other factors may restrict access or limit the ability to expedite a thorough necropsy, the tissue sampling and ranking below should facilitate prioritization of sample collection for diagnostic evaluation. Within reason, every effort should be made to collect the high priority samples with each stranding. The ultimate disposition of tissues will be the responsibility of the lead government agency or regional marine mammal coordinator within the respective area.

ALL requests must be cleared by the regional coordinator prior to shipping to researchers.

HIGH PRIORITY SAMPLES:

For all killer whales that strand, attempt tissue collection of the samples listed below regardless of post mortem condition of carcass.

Tissue	Test	Sample	Preservation	√
As many representative tissues as possible	Histopathology	See Guidelines (*)	Formalin	
Blubber and skin/Liver/Kidney	Toxicology Contaminants	3 cm ³	Aluminum foil and freeze	
Skin	Genetics	1 cm ³	Freeze or DMSO	
Oropharynx/tonsil/blowhole	Molecular studies and culture	Dry swabs and with transport media	Place in plastic bag and chill	
Mammary gland	Bacteriology/cytology	3 cm ³ tissue	Place in plastic bag and chill	
Eye	Clinical chemistry	Aspirate 3-5 ml of vitreous	Red top tube and chill	
Genital slit/ Urogenital canal	Molecular studies and culture	Dry swabs and with transport media	Place in plastic bag and chill	
Ovary	Reproductive and molecular studies	Dry swab and intact ovary	Place in plastic bag and chill	
Morphometrics and photographs	Identification	Digital or slide film	Disc	
Lung/regional lymph nodes/spleen	Molecular studies and bacteriology	2x2 cm tissue	Place in plastic bag and chill	
Post mortem blood sample	Serology and bacterial culture	10-20 ml	Collect in red top tubes and chill	
Stomach and small intestine	Biotoxin assay, stomach content analysis	Ligated	Place in plastic bag and freeze	
Urinary bladder/bile	Biotoxin assay, cytology/culture/urinalysis	5-10 ml	Sterile plastic bag and freeze	

Revised May 15, 2014

INTERMEDIATE PRIORITY SAMPLES:

Collect tissues below if sufficient time and carcass is reasonably fresh (code 1-3).

Tissue	Test	Sample	Preservation	√
Small intestine	Parasitology	Ingesta	Plastic bag and chill	
Tonsil	Histopathology	See Guidelines (*)	Formalin	
Tonsil	Molecular studies	5 gm	Plastic bag and chill or freeze	
Mandible	Sonar related injury	Internal mandibular fat	Histopathology	
Head	Anatomy	Intact	Plastic bag and freeze	
Uterus	Molecular studies	Dry swab	Place in plastic bag and chill	
Brain, liver, kidney, spleen, lymph nodes and lung	Virus Isolation	5 gm	Individual plastic bags and chill or freeze	
Ears	Histopathology	Peribullar fat	Formalin	
Ears	CT scan	Intact	Plastic bag and freeze	
Bile	Toxicology Contaminant	1-2 mL	Glass vial and freeze	
Feces	Toxicology Contaminant	4-5 g	Solvent rinsed glass jar and freeze	
Liver	Trace mineral and vitamin analysis	5 cm ³	Plastic bag and freeze	

LOW PRIORITY SAMPLES:

If there is sufficient time and resources available, the following samples and morphometrics should be collected.

Tissue	Test	Sample	Preservation	√
Dorsal fin	Anatomy	Excise intact	Seal in plastic and freeze	
Teeth	Aging	1-2 intact	Plastic bag	
Organs	Weight	Intact	Fresh	
Mandible	Morphometric study	Intact	Plastic bag and freeze	
Blubber measurement	Morphometric study	Collect and document	Record information	

At the time of necropsy, the tissue sampling checklist (Appendix I) and request lists (Appendices IV) should be consulted and tissues from all major organs and lesions collected for histopathology and representative samples frozen for ancillary studies.

The tissue checklist is designed to follow the sequential post mortem examination of the whale. As organs are excised and appropriate tissues collected and preserved, please mark off the right hand column with an "x".

TISSUE SAMPLE SIZE AND PRESERVATION

Revised May 15, 2014

*Guidelines for fixation of tissues for histopathologic evaluation: preserve all lesions and as many of the tissues listed below as possible in 10% buffered formalin. Tissue samples should be between 3-5 cm² in area and up to 0.5 to 1.0 cm in width and immersed in a ratio of 1 part tissue to 10-15 parts formalin. If electron microscopy (EM) fixative such as glutaraldehyde is available, preserve minced (1-2 mm³) pieces of kidney, liver, spleen and lung.

Representative 3-5 cm blocks of tissue from lesions and major organs (e.g., lung, liver, kidney, spleen) should be placed in individually labeled small (preferably Whirl-pak[®]) plastic bags and placed on dry or wet ice for initial storage and transportation. Also, collect post-mortem serum (from heart blood), urine, eye fluid, bile, ingesta, and any abnormal fluid accumulations. Heart blood should be spun as soon as possible to limit the degree of hemolysis. Upon arrival to a diagnostic or reference laboratory, samples should be frozen at -70 degrees Celsius. If this is unavailable, temporary storage in conventional freezer without automatic defrost cycle is acceptable. A 1-2 cm block of skin, muscle or flipper for genetic analysis should be excised and foil-wrapped and frozen. The sample can be placed in DMSO/saline solution if there is likelihood that the samples cannot remain frozen until they reach their final destination, but freezing without preservative is preferred.

For each lesion, up to 2-3 swabs may be obtained and samples should be chilled for transport to a diagnostic facility. In addition to routine TSA and blood agar cultures, special media for isolation of halophilic bacteria should also be inoculated.

Revised May 15, 2014

APPENDIX II: Pathogens reported in killer whales

Table 1: Pathogens detected directly or via serology in killer whales

Agent	Reference	Location
Bacteria		
<i>Brucella</i> spp.	Jepson et al., 1997; Raverty et al., 2004	Northeastern Atlantic and Pacific
<i>Edwardsiella tarda</i>	Ford et al., 2000	Northeastern Pacific
<i>Salmonella</i> spp.	Ridgway, 1979; Colegrove et al., 2010	Northeastern Pacific and captive
<i>Burkholderia pseudomallei</i>	Hicks et al., 2000	Captive
<i>Clostridium perfringens</i>	Walsh et al., 1994	Captive
<i>Erysipelothrix rhusiopathiae</i>	Young et al., 2002; Bossart et al., 1988	Northeastern Pacific and Captive
<i>Nocardia asteroides</i>	Sweeney et al., 1976	Captive
<i>Nocardia farcinica</i>	St. Leger et al, 2009	Captive
<i>Nocardia otitidiscaviarum</i>	Dunn et al., 2001	Captive
<i>Pseudomonas aeruginosa</i>	Rozanova et al., 2003	Avacha Gulf (Kamchatka)
<i>Streptococcus</i> sp., beta-hemolytic	Greenwood and Taylor, 1985	Captive
<i>Staphylococcus aureus</i>	Power and Murphy 2002	Atlantic
Viruses		
Cetacean pox like virus (Orthopoxvirus)	Van Bresseem et al., 1999	Not Reported
Hepatitis-B like virus	Bossart et al., 1990	Captive
Influenza (suspected)	Ridgway, 1979	Captive
Cutaneous papilloma-like virus	Bossart et al., 1996	Captive
West Nile Virus	St. Leger et al, 2011	Captive
Fungi		
<i>Aspergillus fumigatus</i>	Reidarson et al., 1999	Captive
<i>Candida albicans</i>	Greenwood and Taylor, 1985; Ridgway, 1979; Sweeney et al., 1976	Captive
<i>Cunninghamella bertholletiae</i>	Kakizoe et al., 2012	Captive
<i>Saksenaeva vasiformis</i>	Reidarson et al., 1999	Captive

Revised May 15, 2014

Table 2: Endoparasites identified or suggested by serology in killer whales

Parasite	Reference
Acanthocephala	
<i>Bolbosoma niponicum</i>	Heptner et al., 1976
<i>Bolbosoma physeteris</i>	Heptner et al., 1976
Cestoda	
<i>Phyllobothrium sp.</i>	Dailey and Brownell, 1972
<i>Trigonocotyle spasskyi</i>	Dailey and Brownell, 1972
Nematoda	
<i>Anasakis simplex</i>	Dailey and Brownell, 1972
<i>Anasakis pacificus</i>	Heptner et al., 1976
Amphipods	
<i>Cymus orcini</i>	Leung, 1970
Trematoda	
<i>Campula sp.</i>	Gibson et al., 1998
<i>Fasciola skrjabini</i>	Dailey and Brownell, 1972
<i>Leucasiella subtilla</i>	Heptner et al., 1976
<i>Oschmarinella albamarina</i>	Gibson and Bray, 1997
Protozoa	
<i>Kyaroikeus cetarius</i>	Sneizek et al, 1995; Schulman and Lipscomb, 1999
<i>Toxoplasma gondii</i> and <i>Sarcocystis spp.</i>	Gibson et al., 2011

Revised May 15, 2014

APPENDIX III: The One Hour Necropsy Protocol

Time and tides can work against any investigation. Occasionally, the time allowable for an investigation is extremely limited. When this is the case, efficient data and sample collection are critical for safety and maximum learning. To facilitate this, the following check list can be performed in order. In all cases, tissues should be collected as large samples and then subsampled per Appendix I. This will maximize data and sample collection and can be concluded at any time.

- Capture Level A data – location, date, age class, sex (if possible to determine)
- Collect photos from all sides and of all surfaces visible. Turn the animal if at all possible to facilitate image capture.
- Collect basic morphometrics – length (critical measurement), girth (1/2 times 2 often works best), dorsal fin height and base length.
- Examine the dorsal fin for evidence of a tracking device or scar from such a device. If found, collect device or measure and photograph the scar.
- Flense blubber and look specifically for indications of hemorrhage, bruising, or broken bones. These could include ribs, vertebrae, or the skull so try to examine as widely as feasible.
- Collect skin/blubber from the dorsum if feasible.
- Collect skeletal muscle
- Open the abdomen
- Collect abdominal fluid, liver, kidney, spleen, lymph nodes, gonads, uterus (if applicable), and urine
- Open the thorax – an incision in the diaphragm will facilitate quick access but limited visualization
- Collect heart, lung, trachea, thymus (if present), larynx, and tonsils
- Collect stomach content (or whole stomach – as feasible), intestinal content and intestinal sections
- Collect esophagus
- Remove 2-3 teeth from the middle of the arcade on the most accessible mandible side
- Disarticulate the head, open the skull, remove and collect the brain.

Revised May 15, 2014

APPENDIX IV: Researchers requesting killer whale tissues

Test	Sample	Investigator	Contact information
Algal toxin	Ingesta (stomach) , Liver/Bile /Feces/urine	Dr. LeFebvre	206-302-2454
Anatomy	Mandible	Dr. Barrett-Lennard	604-659-3428
Anatomy	Head	Dr. Barrett-Lennard	604-659-3428
Anatomy (US)	Dorsal fin	Dr. Hanson Dr. Andrews	206-860-3220
Anatomy (US)	Whole skeleton	Dr. Hanson	206-860-3220
Bacteriology (Canada)	Multiple tissues	Dr. Raverty	604-556-3003
Bacteriology (US)	Multiple Tissues	Dr. Goldstein	530-754-7953
Brucella culture	Lung, brain, CSF, uterus/testes, and lymph nodes	Dr. Byrne, UC Davis	
CT scan	Ears/Head	Dr. Hanson Dr. Dennison	206-860-3220
Cell culture	Representative fresh tissues	Dr. Wise	207-228-8050
Clinical chemistry	Serum sample	Dr. St. Leger	619-225-4259
Fatty acid analysis	Blubber and skin	Ms. Ylitalo	206-860-3325
Genetics	Skin biopsy	Dr. Barrett-Lennard Dr. Parsons Dr. Morin	604-659-3428 206-302-2428 858-546-7165
Hematology (US)	Blood (fresh/unfrozen)	Dr. St. Leger	619-225-4259
Histopathology	Formalin fixed tissues	Dr. St. Leger Dr. Raverty Dr. Rotstein	619-225-4259 604-556-3003 240-238-1165
Hormone analysis	Serum and feces	Dr. St. Leger	619-225-4259
Molecular studies/ PCR	Multiple tissues	Dr. Raverty	604-556-3003
<i>Mycoplasma</i> culture (US)	Swabs of respiratory tract, middle ear and genital slit/urogenital canal	Dr. Frasca	860 486-1138
Parasitology	Ingesta and parasites	Dr. Kinsella	415-289-7346
Prey analysis (US)	Stomach contents	Dr. Hanson	206-860-3220
Prey analysis (Canada)	Stomach contents	Dr. Ford	250-756-7245
Radionucleotides	Skeletal muscle	Dr. Dasher	907-474-6840
Reproductive	Formalin, intact	Dr. Hanson	206-860-3220
Serology	Heart blood	Dr. Saliki/O. Nielsen	405-744-6623/204-983-5126
Toxicology - POPs	Blubber, liver and kidney	Ms. Ylitalo	206-860-3325
Trace mineral and vitamin A analysis	Liver and kidney	CAHFS Lab	530-752-8700
Viral hunting (molecular techniques)	Brain, trachea, lung, liver, spleen, skin, lymph node, and feces	Dr. Anthony	760-500-4639
Virology	Multiple tissues: EDTA blood	Dr. Saliki/Dr. Raverty	405-744-6623/604-556-3003

Revised May 15, 2014

APPENDIX IVA: Specific research / case evaluation requests

Below are currently approved requests and protocols (as of March, 2014).

1. Dr. Lance Barrett-Lennard, Vancouver Aquarium Marine Science Centre 845 Avison Way Vancouver, British Columbia V6G 3E2 Phone: 604-659-3428, Email: barrett@zoology.ubc.ca
 - **Intact skull or lower jaw (mandible) for morphometric studies.** Please contact Dr Barrett-Lennard before conducting the post mortem.
 - **Skin samples.** Punch biopsy or excised skin, including epidermis and hypodermis. Placed in either DMSO/saline solution and refrigerate or wrap in aluminum foil and freeze.

2. Dr. Rebecca Pugh, NIST 219 Fort Johnson Road Charleston, South Carolina 29412 Work: 843-762-8952 Email: Rebecca.pugh@nist.gov
 - **Fresh dead tissue** samples for ongoing efforts to collect and appropriately archive harvested tissue samples from multiple indicator species. Please call before conducting necropsy for additional details.

3. Dr. Mike Kinsella, HelmWest Laboratory, 2108 Hilda Avenue, Missoula, Montana 59801, USA. Wormdwb@aol.com
 - **Preservation of parasite samples for ongoing speciation studies.** Samples of stomach worms, frozen in Whirl-pak® bags at -70, alternatively, freeze in standard freezer, ship overnight on dry ice. All other parasites, preserve in 90% ethanol in Whirl-pak® bags. If possible, let flatworms relax in tap water in cooler overnight before fixation.

4. Mycobacteria and Brucella Section Diagnostic Bacteriology Laboratory National Veterinary Services Laboratories 1800 Dayton Road Ames, IA 50010 Phone: 515-663-7347 Fax: 515-663-7904
 - **Frozen tissue samples for *Brucella* culture.**

5. Dr. Bradley Hanson, NOAA/NMFS/Northwest Fisheries Science Center 2725 Montlake Blvd. E Seattle, WA 98112 Work: 206-860-3220 Fax: 206-860-3475, Cell Phone: 206-300-0282 Email: Brad.Hanson@noaa.gov
 - **Stomach content, head, and dorsal fin for anatomic analysis.** Please either ligate the esophagus and duodenum or remove all the stomach contents, then freeze for analysis. Dorsal fin, remove 10 cm below insertion, place in plastic bag and freeze. Head may be disarticulated, then placed in plastic bag and frozen.
 - **Ovaries.** Please preserve intact in formalin.

6. Dr. John Ford, Fisheries and Oceans Canada Pacific Biological Station 3109 Hammond Bay Road, Nanaimo, BC, Canada V9T 6N7 Work: 729-8375 Fax: 250-756-7053 Email: john.k.ford@dfo-mpo.gc.ca

Revised May 15, 2014

7. Dr. Stephen Raverty, Animal Health Center 1767 Angus Campbell Road Abbotsford, BC, Canada V3M 2G3 Phone, work: 604-556-3003 Phone (work): 800-661-9903, Email: Stephen.Raverty@gems3.gov.bc.ca
 - **Fresh and fixed tissue samples for ongoing investigation into mortality of stranded killer whales.** Please call before conducting necropsy for additional details. Please also send frozen samples of tongue and masseter muscle as well as diaphragm for *Apicomplexa* testing, frozen stomach contents and bile for algal toxin testing, multiple frozen tissues for bacteriology, and frozen samples of kidney and liver (wrapped in foil) for trace mineral analysis.
 - **Samples of liver, kidney, brain and blubber (toxicologic investigation) from stranded killer whales.** Please record species, age, location and date. Wrap 30-50 gm of tissue in aluminum foil then freeze at -20C, ship on dry ice.

8. Dr. Jeremiah Saliki, University of Georgia Athens Diagnostic lab 0149 Athens Vet Med Diagnostic Lab. Athens, GA 30602 Phone 706- 542-5906, jsaliki@uga.edu
 - **Post-mortem heart blood and frozen tissue samples.** Serology, molecular studies and attempted virus isolation on marine mammal specific cell lines. Remove serum from blood sample and freeze at -80C. Various tissues (tonsil, spleen, lymph nodes, kidney, lung, kidney) for virus isolation. If possible, ship chilled same day for overnight delivery; if not, store frozen until shipped.

9. Dr. J. L. Stott, Marine Mammal Immunology Laboratory, Veterinary Medicine PMI VM3A Rm 4206, One Shields Avenue, University of California Davis, CA 95616, Phone: 530-752-2543 Cell: 530-902-3971, E-mail: jlstott@ucdavis.edu
 - **Blood samples for immune function testing of live animals.** Only for code 1 (live stranded) cases. The appropriate vacutainers and instructions for use are listed in Appendix IVa. Prior arrangements **MUST** be made. Leave messages on **both** lab and cell phones and also send e-mail.

10. Dr. Phil Morin, NOAA/NMFS/Southwest Fisheries Science Center Population Identification Program, 8604 La Jolla Shores Drive La Jolla, CA 92037-1508 Phone: 858-546-5620, E-mail: Phil.morin@noaa.gov and Dr. Kim Parsons National Marine Mammal Laboratory Alaska Fisheries Science Center/NOAA, 7600 Sand Point Way N.E. Seattle, WA 98115-6349, Phone: (206)-526-4041 E-mail: Kim.Parsons@noaa.gov
 - **Skin samples for genetics.** Punch biopsy or excised skin, including epidermis and hypodermis. Placed in either DMSO/saline solution and refrigerate or wrap in aluminum foil and freeze.

11. Dr. Sal Frasca, Connecticut Veterinary Medical Diagnostic Laboratory, Department of Pathobiology and Veterinary Science, University of Connecticut, 61 North Eagleville Road, Storrs, CT 06269-3089
Phone: 860-486-1138. salvatore.frasca@uconn.edu

Revised May 15, 2014

- **Tissue samples for attempted *Mycoplasma* spp isolation.** Swabs or fresh tissue should be aseptically collected from representative levels of the respiratory system, including the blowhole, larynx, trachea, tracheal bifurcation, lungs, mediastinal lymph nodes, middle ear, and genital slit/urogenital tract. Swabs should be chilled and forwarded by courier.
12. John Pierce Wise, Sr., Ph.D. Director, Center for Integrated and Applied Environmental Toxicology Associate Professor of Toxicology and Molecular Epidemiology Bioscience Research Institute University of Southern Maine 178 Science Building 96 Falmouth Street Portland, ME 04103 Phone: 207-228-8047 Email: WiseLab@usm.maine.edu
- **Fresh tissue samples to be cultured and stabilized (“immortalized”) for subsequent toxicological studies and for placement in the marine mammal cell repository for other permitted researchers.** Please collect skin (w/dermis), kidney, liver, bronchus, testes/ovaries, brain from all young animals and call for storage and shipping recommendations.
13. Ms. Gina Ylitalo, NOAA Fisheries / Northwest Science Center 2725 Montlake Boulevard East Seattle, WA 98112 Phone: 206-860-3325, E-mail: Gina.Ylitalo@noaa.gov
- **Samples of liver, kidney blubber with skin, skeletal muscle, bile, and feces. (Contaminant toxicologic investigation).** Please record species, age, location and date. Wrap 30-50 gm of tissue in aluminum foil or place in appropriate glass containers, then freeze at -20C, ship on dry ice (Appendix IX).
14. Dr. Doug Dasher, University of Alaska Fairbanks 905 N. Koyukuk 245 O'Neill Building P.O. Box 757220 Fairbanks, AK 99775-7220 Phone: 907-474-6840, E-mail: dhdasher@alaska.edu
- **Samples of skeletal muscle for detection of Cs 137 and Cs 134 radionuclides.** Please collect **1kg** of dorsal skeletal muscular and freeze (-20 is fine) in a plastic Ziploc or Whirl-pak® bag. Use clean gloves and keep sand or sediments off of the sample. Ship frozen for testing.
15. Dr. Dawn Noren, Research Fishery Biologist, NOAA NMFS Northwest Fisheries Science Center, Seattle, WA Phones: Office: 206-302-2439/ Cell: 206-423-0215, E-mail: dawn.noren@noaa.gov
- **Samples of skeletal muscle to measure muscle myoglobin content and acid buffering capacity** (to assess variability in muscle biochemistry and diving capability with development and across ecotypes). Collect muscle samples from all age carcasses that are in fresh condition (Code 2). Samples are to be collected from the mid-belly of the primary locomotor muscle (*m. longissimus dorsi*). The location of the sampling site is below the anterior insertion site of the dorsal fin. Samples (3X3 inch block) should be completely wrapped in foil, placed in a Ziploc bag, and frozen immediately after collection.

Revised May 15, 2014

APPENDIX IVB: Request for marine mammal post-mortem samples

Name _____
Date of request _____
Affiliation _____
Address _____

Work phone (____) _____
Cell phone (____) _____
Fax (____) _____
Email _____

All sample requests should have a two to five page description of the study to be performed including specifics on related background, the sample(s) required, optimal collection and storage, shipping directions, timeline for sample analysis and plans for integration into larger ecological investigations. This material along with permits, investigator CVs, and shipping account numbers should be provided to Drs. Hanson and Ford (Contact info on the next page).

Sample(s) requested

Purpose of study

Duration of study (start and stop dates)

Instructions for sample preparation

Shipping instructions (Permits? Dry ice? Overnight? Will you pay for shipping?)

Special instructions

Dr. Brad Hanson, NOAA/NMFS/Northwest Fisheries Science Center, 2725 Montlake Blvd. E, Seattle, WA 98112, Office phone: 206-860-3220, Fax: 206-860-3475, Cell phone: 206-300-0282, Email: **Brad.Hanson@noaa.gov**

Dr. John Ford Fisheries and Oceans Canada Pacific Biological Station 3109 Hammond Bay Road, Nanaimo, BC, Canada V9T 6N7 Work: 729-8375 Fax: 250-756-7053 Email: **john.k.ford@dfo-mpo.gc.ca**

Revised May 15, 2014

APPENDIX V: Permitting concerns and authorities

Marine mammals are protected internationally under a variety of treaties and acts. All stranding response should begin with contacting the proper authorities.

In the USA, marine mammals are protected under the Marine Mammal Protection Act and the Endangered Species Act. In Canada, killer whales are covered by the Species at Risk Act (SARA).

International shipment of samples and materials must comply with the Convention on International Trade of Endangered Species (CITES) as well as US Department of Agriculture/ Animal and Plant Health Inspection Service (USDA/APHIS). Permits are required for international exchanges.

USA: NOAA Office of Protected Resources (OPR) <http://www.nmfs.noaa.gov/pr/>
Dr. Teri Rowles. Teri.Rowles@noaa.gov (301) 713-2322 x-178 Stranding network
hotlines: <http://www.nmfs.noaa.gov/pr/health/networks.htm>

CITES: <http://www.cites.org/common/cop/15/doc/E15-30-01T.pdf>

USDA/APHIS: <http://www.aphis.usda.gov/>

US Fish and Wildlife Service: <http://www.fws.gov/>

CANADA: Fisheries and Oceans Canada, <http://www.pac.dfo-mpo.gc.ca/fm-gp/species-especies/mammals-mammiferes/index-eng.html>

Paul Cottrell, DFO Marine Mammal Coordinator (604) 666-9965

SARA: http://www.sararegistry.gc.ca/default_e.cfm

CITES : <http://www.dfo-mpo.gc.ca/acts-lois/cites-eng.htm>

DFO Marine Mammal Response Hotline (British Columbia): (800) 465-4336

Revised May 15, 2014

APPENDIX VI: Pathogen and tissue sample list for Polymerase Chain Reaction Studies

Current list of pathogens that may be screened by polymerase chain reaction. These tests may be conducted on tissues harvested from animals recovered in code 1 and 2 and *in select cases*, code 3. Various laboratories perform these tests.

Pathogen	Tissues
Adenovirus	Lymph node, spleen, lung, liver
Apicomplexa	Diaphragm, skeletal muscle, tongue, brain, lymph node, liver, heart
<i>Bartonella sp</i>	Lymph node, spleen, lung, liver, brain
<i>Brucella spp</i> , marine mammal variant	Lymph node, spleen, lung, brain, CSF, uterus/testes, amniotic fluid
Canine distemper virus	Lymph node, spleen, lung, brain
Cetacean pox (orthopox virus)	Skin, lung, spleen
Dolphin morbillivirus	Lymph node, spleen, lung, brain
Calicivirus, marine	Feces, small intestine, skin lesions
<i>Chlamydophila psittaci</i> -Avian	Lymph node, spleen, lung, brain
<i>Chlamydophila abortus</i> –Ovine	Lymph node, spleen, lung, brain
Circovirus	Lymph node, spleen, lung, brain
<i>Clostridium</i> genotyping (toxin)	Small and large intestine, bacterial isolate
<i>Clostridium piliforme</i> -Tyzzer's disease	Intestine or liver
Coronavirus consensus	Intestine, liver, lung
<i>Coxiella burnetii</i>	Lymph node, spleen, lung, brain, placenta
<i>Cryptococcus gattii</i>	Isolate, genotyping
<i>Cryptosporidium parvum</i>	Small intestine, feces
Enterovirus	Small intestine, heart, lung, brain
<i>Erysipelothrix rhusiopathiae</i>	Lymph node, spleen, lung, brain, ascites
<i>Escherichia coli</i> genotyping - Bovine/Porcine	Bacterial isolate
Filovirus consensus	Brain, lung, spleen, lymph nodes
Flavivirus	Brain, lung, spleen, lymph nodes
Fungus - Universal	Fungal isolate
<i>Giardia lamblia</i>	Feces, small intestine
<i>Helicobacter spp</i>	Stomach, glandular compartment
Hepatitis A,B, and C	Liver
Hepatovirus	Liver
Herpesvirus – Universal (consensus)	Lymph node, spleen, lung, brain, liver, adrenal gland
Influenza Virus – Universal	Lymph node, spleen, lung, brain
<i>Leptospira</i> (multivalent)	Liver, kidney
<i>Listeria monocytogenes</i>	Brain, lymph node, spleen, lung
<i>Morbillivirus</i> - Universal	Lymph node, spleen, lung, brain
<i>Mycobacterium</i> - Universal	Lymph node, spleen, lung, brain
<i>Mycobacterium avium</i>	Intestine, mesenteric lymph nodes, feces
<i>Mycobacterium paratuberculosis</i>	Intestine, mesenteric lymph nodes, feces
<i>Mycoplasma (Mollicutes)</i> - Universal	Lymph node, spleen, lung, nares, oviduct, placenta
<i>Neospora caninum</i>	Lymph node, spleen, lung, brain

Revised May 15, 2014

<i>Nocardia</i> - Universal	Skin, lung, lymph node, spleen
Papillomavirus- universal	Skin, prepuce, vulva, gingiva, tongue
Parainfluenza virus	Lung, lymph node, spleen
Paramyxovirus	Lung, brain, lymph node and spleen
Parapoxvirus-consensus	Lung, skin, genitalia
Picornavirus	Pancreas, small intestine
Poxvirus	Skin, prepuce, vulva, gingiva, tongue
Reovirus	Lung, small intestine, liver, and lymph nodes
Retroviruses-consensus	Lymph nodes, whole blood, spleen, lung
Rhabdovirus	Brain, lymph node, spleen, lung
Rotavirus	Small intestine
<i>Sarcocystis spp</i>	Lymph node, spleen, lung, brain, skeletal muscle, diaphragm, tongue
<i>Sarcocystis neurona</i>	Lymph node, spleen, lung, brain, skeletal muscle, diaphragm, tongue
<i>Salmonella</i>	Intestines, feces, isolate
<i>Streptococcus</i>	Isolate
<i>Toxoplasma gondii</i>	Lymph node, tongue, liver, lung, brain
<i>Trichinella spp</i> consensus	Tongue, diaphragm
West Nile virus	Brain, lung, lymph node, spleen
Western Equine Encephalitis virus	Brain, lymph node, spleen, lung,

Revised May 15, 2014

APPENDIX VII: Marine mammal blubber sampling protocol

Tissue Sampling for Chemical Contaminant Analyses

Supplies for sampling will include:

- Four 12" x 13" solvent-rinsed Teflon sheets, solvent-rinsed 17-mL Teflon screw top vials for blood, and 4-mL amber vials for bile.
- Four 18 oz. Whirl-pak® bags (4.5" x 8.5") or Zip-Lock bags
- Ballpoint and marking pens

Sampling Protocol:

- Priority for collection of samples is: full-thickness blubber with skin, liver, muscle, blood (when possible), and bile.

Blubber collection procedures: It is important to use standardized sampling procedures so that, even when there are low levels of contaminants present, the differences may be attributed to biological processes and contaminant exposure and not to variation in the collection process. The following procedures are essential to prevent cross-contamination of tissues within an animal and ensure uniformity of samples among animals.

1. Collect full-thickness blubber with skin attached, if possible. This reduces variation caused by possible composition differences within tissues of the same animal. It also provides us with uniform samples and information from all participating organizations which can be directly compared based on the demographics of the animals. Sample size: blubber 10 – 20 g. NOTE: please collect full thickness blubber from the dorsal region (behind the dorsal fin).
2. If possible, rinse all instruments with isopropyl alcohol before each blubber sample is sampled. This will minimize cross-contamination of tissues.
3. Keep samples as cold as possible after collection. Some of the organic contaminants are volatile or are degraded by compounds released during cell death. In addition, lipids may be lost (e.g., leaching may occur) if the samples are not kept as cold as possible. To decrease changes in contaminant levels and lipid due to these processes, keep the samples on ice following the necropsy and freeze as soon as possible in a –20°C freezer or colder freezer (e.g., –80°C freezer). For fatty acid analyses, the samples should be stored in a –80°C freezer.

For tissue collection, use a stainless steel knife and clean and rinse the knife with alcohol between necropsies of each animal. Wrap each tissue sample in a pre-rinsed Teflon sheet

Revised May 15, 2014

or in a pre-rinsed vial and then place sample into a labeled Whirl-pak[®] or a Ziploc bag.

Label each bag with:

- Animal ID Number
- Species
- Tissue Type
- Date Collected

Remove as much of the air as possible from the bag before it is sealed.

Place samples on ice. As soon as possible, freeze at lowest temperature available.

Please provide copy of full necropsy report.

Shipment of Samples:

Ship frozen samples on blue ice or ~5 lbs dry ice, early in the week via FedEx overnight to: Gina Ylitalo/Jennie Bolton, NWFSC, ECD, 2725 Montlake Blvd. E., Seattle, WA 98112-2097.

Call Gina (206-860-3325) or Jennie (206-860-3359) the day the samples are shipped with the invoice number for tracking, if necessary:

**Marine Mammal Tissue Contaminant Analyses Environmental Conservation Division,
Northwest Fisheries Science Center
National Marine Fisheries Service, National Oceanic and Atmospheric Administration
2725 Montlake Blvd. East, Seattle, WA 98112-2097
Phone: (206) 860-3325, FAX (206) 860-3335**

Revised May 15, 2014

APPENDIX VIII: Collection of samples for contaminant analysis

OBJECTIVES: To obtain relatively fresh tissues to determine concentrations of various contaminants.

APPROPRIATE SAMPLE SOURCES

All code 2 (fresh dead) animals and necropsy material.

SAMPLING PROTOCOL

1. Obtain 50- 75 grams (an absolute minimum of 10 grams is required for the basic analysis) of the following tissues:
 Skin Kidney Heart
 Blubber Liver Brain
 Muscle Lung Testes/Ovaries
2. For metals analysis: Place in plastic collection bags, Whirl-pak[®] bags or conical tubes (NO ALUMINUM FOIL CONTACT).
3. For organics analysis: Place in brown amber hexane washed vials (NO PLASTICS CONTACT)
4. Label with animal ID and tissue type.
5. Samples should be frozen immediately (-80°C if possible).

Additional sampling

For genetic analysis: place about 2 g of tissue in a 2 ml plastic vial. Label appropriately. Freeze at -20 deg.

SHIPPING PROTOCOL

1. Ship with dry ice (preferred method) in a Styrofoam box as soon as possible via the fastest method, overnight is best. Please call as soon as possible to let us know that samples are on their way. (See contact info.) We will accept weekend deliveries; however call to get the weekend address.
2. Enclose a copy of official documentation (i.e. NMFS Level A in the case of stranders, Subsistence Harvest Data Forms, or other appropriate official documentation) detailing collector, location, circumstances, and animal information. (Our NMFS permit requires that we keep track of the origins of all of our tissues and document who obtained samples for us.)
3. If using FedEx, our Account number is 2546-3232-5.
4. Send samples to: Wise Lab, 476 Science Bldg, 96 Falmouth St, Portland, ME 04103

CONTACT INFO

See our website at <http://www.usm.maine.edu/toxicology/research/nmcl.html>

Sandy Wise

Phone: 207-228-8047

E-mail: swise@usm.maine.edu

Revised May 15, 2014

APPENDIX IX: Collection of samples for biotoxin analysis

Supplies

- * Normal sized samples: 50-mL plastic centrifuge tubes or other plastic tubes
- * Large samples: sealable/Ziploc plastic bags or bottles

Prey Fish

If possible, the species should be identified before freezing. Small fish should be collected and frozen, then shipped whole. For large species, stomach contents (whole stomach), liver and flesh should be sampled and stored separately. Minimum of 5 g (up to 50 g) flesh should be obtained. All tissues can be stored frozen (-20°C) in Ziploc bags until shipment on dry ice.

Mammals

Sampling of code 1 or 2 animals is preferred although code 3 animals and later are still useful for toxin analysis.

The most useful tissues/fluids for confirming biotoxin exposure are generally feces, urine liver, and stomach contents. However, samples from additional compartments (intestinal contents, kidney, lung, brain, whole blood, serum) are also valuable depending on the toxins of interest, and are useful for metabolism and body burden studies. All samples should be immediately placed in a cooler on ice and frozen (-20°C or -80°C) as soon as possible after collection. Samples should be shipped on dry ice to the laboratory for analysis. Prior to shipping samples, please contact receiving laboratory to ensure proper receipt of the samples and sample data.

All sample containers must be labeled with the animal ID and sample type in indelible ink (include date and species if space permits), such that labels remain legible when wet. When this is not possible, a small tag containing sample information inserted inside the sample container may be useful. A copy of the NOAA level A datasheet for each animal must accompany each shipment. If this datasheet is not available, please include the following data with the sample shipment: species and common name, stranding date (typically date of initial observation), stranding location (latitude/longitude in decimal degrees), animal length, weight, condition code, sex, and any additional relevant information. In addition, also send a digital version of data sheets and sample logs to your contact at the laboratory. Please include alternate animal IDs when multiple field ID numbers exist. Animal IDs should be consistent with those submitted to the national stranding database. Sample containers and volumes listed below are recommended but not required.

Urine - Collect a minimum of 1 ml urine, more if available (up to 50 ml). Store frozen (-20°C) in capped plastic centrifuge tubes.

Feces - Collect a minimum of 5 g (up to 50 g). Store frozen (-20°C) in capped plastic centrifuge tubes or other container suitable for freezer storage.

Intestinal contents - Collect a minimum of 5 g (up to 50 g). Store frozen (-20°C) in capped plastic centrifuge tubes or other container suitable for freezer storage.

Revised May 15, 2014

Indicate which portion of the intestine was sampled (e.g. upper, mid-, lower intestine). Bile is also useful for analysis of lipophilic toxins.

Stomach contents – Collect a minimum of 5 g (up to 50 g) of solid or semi-solid contents if available. Store frozen (-20°C) in capped plastic centrifuge tubes or other container suitable for freezer storage. If stomach fluid only is available, collect at least 5ml in a plastic tube or vial. Indicate which portion of the stomach was sampled if applicable (e.g. pyloric, fundic, etc.). If stomachs contain undigested or partially digested prey or food items, please collect separately from gastric fluid. Any indication of prey species or identification of contents are very valuable to interpretation of analyses.

Liver, kidney, lung, spleen, brain – collect a minimum of 5 g (up to 50 g). Store frozen (-20°C) in plastic tubes, Ziploc bags or other leak-proof containers.

Serum – obtain serum by centrifugation (1500-3000 x g; 5 minutes) of whole, heparinized blood. The top layer is the serum. Collect >0.5 ml of serum and store frozen (-20°C) in a plastic tube.

Whole blood - Heparinized whole blood can be spotted directly onto blood collection cards and stored at room temperature in the presence of desiccant pouches. Blood cards with detailed instructions can be obtained from your contact at the Marine Biotoxins Program laboratory. If blood cards are not available, liquid whole blood may still be useful.

**Please note, if samples are to be analyzed for multiple algal toxins, a larger amount of sample is needed in order to perform multiple toxin extractions.*

Revised May 15, 2014

APPENDIX X: Webpage resources for submission forms

NVSL: http://www.aphis.usda.gov/library/forms/pdf/VS_Form10_4.pdf

CAHFS Lab:

http://cahfs.ucdavis.edu/local-assets/pdfs/StandardSubmissionForm_6-13.pdf

UC Davis Marine Mammal Diagnostic Lab: <http://www.vetmed.ucdavis.edu/whc/mehds/>

Connecticut Diagnostic Lab:

<http://cvmdl.uconn.edu/forms/CVMDL%20Submission%20Form.pdf>

Revised May 15, 2014

APPENDIX XI: Photography instructions and considerations

Capturing gross images allows the prosector to share what they saw after the fact. Once the carcass is left or cut, the images from the examination are lost unless captured for further review. Digital images are an easy way to quickly document lesions and changes for later discussion and consultation. In a worse-case scenario, almost everyone has access to a phone with camera abilities. The preferred method of image capture is a dedicated camera with 1-3 memory cards to facilitate capture of numerous large image files. If all else fails, use your cell phone!

General rules:

1. Photograph the dorsal fin, saddle patch, eye patch, and any other identifiable features (scars, coloration, etc) so the animal can be traced back to life history images.
2. Be sure to start with a **case identifier** in at least the first images so that the case can later be associated with the images
3. Take a **series of external images** to note carcass condition and location prior to initiating the examination
4. Put in **items for scale** – preferably a ruler but a pen, coin, or even a gloved hand will do to demonstrate how big something is.
5. Put scale items to the side rather than the center of the image – they are for scale. They should not obstruct the lesion.
6. Take **overall (wide angle) and close-up images** so that the lesions are easy to see and can be put into context.
7. Take **images before collecting samples** – but if you forget, getting an image after collecting samples is better than not getting an image.
8. **Remove blood/sand/debris** as best as possible to obtain a clean, distraction free photo
9. Make sure the **image is in focus** before moving on
10. Take images of the external surfaces, the mouth, the genitalia, the thorax, the abdomen, gastric contents, and anything that appears unusual or abnormal.
11. Download and label the images within 24 hours of the completion of the gross necropsy examination. Do not consider the exam completed until this is done.
12. Photo adjustments to consider post exam:
 - Adjusting brightness or contrast
 - Cropping the image
 - Modify background colors
 - Remove excess glare

Note: A photo identifier is attached at the end of this protocol for you to cut out and use as a scale and to identify the samples. You may want to print and laminate this or place in a plastic bag to facilitate cleaning.

Revised May 15, 2014

APPENDIX XII: Ancillary imaging instructions

CT imaging

CT imaging of dead animals is indicated to evaluate for evidence of bone trauma, for evidence of thoracic injury or abnormal gas accumulations, and to a lesser degree to evaluate the soft tissues. The code of the cadaver is important and any evidence of autolysis/decomposition (including histological) means caution must be applied to any gas accumulations observed.

CT gantries have limitations. Table weight limitations are typically around 300lb, although modified tables are available at some veterinary schools that can accommodate far greater weight. The gantry size will also be a potential limitation. Gantry diameter for CT is typically 80-90cm in width (although some larger gantries do exist) but height is less than width because of the table, which can reduce size to 60cm in some cases. The cadaver cannot touch the gantry during scanning (there must be a small amount of air between the cadaver and the gantry for successful scanning). Knowledge of weight and size limitations prior to organizing scanning is strongly recommended. In smaller cadavers removal of the dorsal fin prior to scanning may permit whole body evaluation. In larger animals decapitation may be required in order to scan the head.

Imaging protocol multislice scanner:

- 0.5mm slice thickness through each individual ear, axial scan mode, bone reconstruction algorithm only
- 3mm slice thickness through the head and 3-5mm slice thickness through the thorax and abdomen using soft tissue and bone reconstruction algorithms. Helical scan mode can be used (pitch equivalent to single slice pitch of 1.4-1.7)

Imaging protocol single slice scanner:

- 1mm slice thickness through each individual ear (if possible) or both ears simultaneously, bone reconstruction algorithm only
- 3mm slice thickness through the head and 3-5mm slice thickness through the thorax and abdomen using soft tissue and bone reconstruction algorithms. Helical scan mode can be used with pitch 1.4-1.7

Revised May 15, 2014

APPENDIX XIII: Oil spill concerns and sampling

Oil spill events can involve a variety of marine species. Killer whales are no exception. While killer whales have the ability to swim away from specific areas, oil events with wide dispersal can impact both water and prey quality and condition. The duration of effects may be long-lasting. Thus, if killer whales strand in areas where oil contamination is, was, or could be a concern specific determinations for the effects of oil are indicated. Oil spill response is generally overseen by specialists focused in this arena. Event reporting as well as response assistance is available 24/7 via:

<http://www.vetmed.ucdavis.edu/owcn/>

This web site provides information on contact personnel as well as forms for data collection and chain of custody reporting. It is an invaluable resource for oil spill events in the United States.

IMPORTANT: DO NOT enter an oiled area without proper training and personal protection

Oil spill response is considered an investigative action and all efforts should be conducted:

1. By personnel with knowledge of safety concerns and actions relative to oil and oil spills
2. By persons with knowledge and abilities relative to evidence collection
3. As a team effort with folks interested in investigating oiling events, the effects of oil, and the general health of killer whales in a specific area.

Measuring the effects of oil and petroleum-based products as well as dispersants may involve measuring for metabolic as well as toxic products. When such conditions are a consideration, collection of numerous tissues in Teflon-coated bags or within aluminum foil as dictated by the analysis to be performed will facilitate further evaluations. Photo documentation of lesions and conditions is especially important.

Chain of custody (COC) rules are an important element in oil spill sample management. Before logging any samples be sure you have discussed this effort with the event manager.

While they are still in draft form, NOAA's marine mammal oil spill response guidelines, which include an evidence collection protocol and a petroleum hydrocarbon tissue sampling protocol among other things, are available at:

http://www.nmfs.noaa.gov/pr/pdfs/health/eis_appendixl.pdf

Revised May 15, 2014

APPENDIX XIV: Considerations and sampling for live stranded killer whales

Killer whales can and do strand live. When this happens, the events can be single strandings or associated with mass stranding events. In either situation, steps should be taken to assure:

1. Safety of humans in the area
2. Safety and humane care for the whales
3. Collection of scientific samples/data as feasible
4. Protection of wild populations

Management of live stranded animals includes efforts such as cooling, wetting, providing shade and even assuring proper orientation of the animal on its ventrum to facilitate breathing. The response efforts for killer whales are of a great magnitude owing simply to the size of many killer whales. The first step in managing such an event is to contact the local authorities that work with marine mammals. A team approach is generally the best first step to assure a positive result. Overall management of live strandings is beyond the scope of this work. However, general information is available through the Geraci and Lousbury's 2005 book *Marine Mammals Ashore*.

Two main considerations for sample collection

1. Safety – killer whales are large and strong. Even when beached, these animals have the ability to swing wildly and rapidly. This should always be considered first and foremost
2. Reasonability – If the animal is about to die or will be euthanized, many of these samples can be collected post-mortem from the fresh carcass.

Depending on the animal's physical condition, data and samples that can be collected include:

1. Morphometrics – specifically total length, dorsal fin height, pectoral fin characteristics
3. Image capture (Photos) including evidence of human interaction – nets, lines, ship strike injuries, prop wounds
4. Skin sample collection via scrape for genetics
5. Blood collection – ideal samples are approximately 50mLs and include 3 mLs for a CBC and the rest of the blood is allowed to clot and separated to collect serum. Serum should be evaluated for blood chemistries and hormones and the remaining material should be banked for additional evaluations.
6. If possible, fresh whole blood should be collected for immunology studies – see research requests – Jeff Stott's lab.
7. Lesion sampling – scrapes, swabs for microbiology and molecular analysis

A note on euthanasia:

Unfortunately, circumstances arise where euthanasia is necessary for stranded animals. These include:

- Disabling injuries such as boat strike or penetrating wounds

Revised May 15, 2014

- Significant hemorrhage
- Unresponsive hyperthermia
- Massive skin blistering and/or sloughing
- Loss of reflexes or muscle tone

Important considerations for euthanasia are that the process be quick and complete with minimal discomfort for the animal in question and safe for others in the area. Authorities overseeing stranding response may have a specific protocol for euthanasia and should be contacted. In some cases, allowing the animal to die naturally may be more humane than intervening. Final considerations are that the effort minimally impact scientific specimens and that the process be completed in such a manner as to appear professional to all public onlookers.

Ballistics may be used by trained individuals to avoid drug residue problems but are not recommended for larger killer whale. If such a manner of euthanasia is selected as best, the animal should first be curtained off to prevent public viewing. The site of the bullet entry is critical (see Harms et al., 2014 – below).

Routine euthanasia with barbiturate overdose is feasible for killer whales. Drug volume requirements should be carefully determined for animal size. Newborn killer whales are approximately 300-400 pounds. Adults can weigh 10,000-16,000 pounds. Drug residues including impacts on scavengers and long half-life in the aquatic environment are a consideration. Carcass disposal options may make barbiturate administration an unreasonable manner of euthanasia. If barbiturates are used, the preferred manner of administration is via cardiac stick following premedication with a sedative (Geraci and Lounsbury, 2005). Attempts to use the tail or peripheral veins may be thwarted by vascular shunting or shock. Without the use of a premedicating sedative, the animal may begin to rhythmically raise and lower the tail in a swimming motion. This motion, “flurrying” can propel the animal from its original position.

Given the large size of killer whales, methods developed for baleen whales may be more appropriate for this species. Alternate methods of euthanasia employ tranquilization with drugs such as midazolam, acepromazine, and xylazine followed by saturated KCl solution (Harms et al., 2014).

[Harms, C.A., W. A. McLellan, M. J. Moore, S. G. Barco, E. O. Clarke EO, V. G. Thayer and T. K. Rowles. 2014. Low residue euthanasia of stranded mysticetes. Journal of Wildlife Diseases 50:63-73.](#)

Revised May 15, 2014

APPENDIX XV: Cetacean ear extraction and fixation protocol

Introduction

There is an increasing concern about the impacts of anthropogenic underwater noise on cetacean populations. For this reason, the analysis of the ears, especially for the presence of possible lesions in the organ of Corti represents a fundamental effort to assess the implication of acoustic trauma in stranding events. These are otherwise not detectable by routine histopathologic techniques.

The difficulty relies in obtaining fresh material rapidly fixed by proper solutions and in accessing the cochlea by decalcifying methods without affecting the inner ear soft structures.

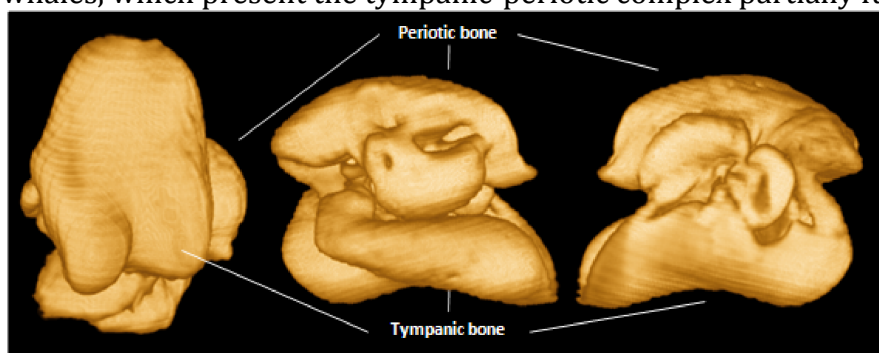
The Laboratory of Applied Bioacoustics (LAB) has developed a fast decalcification protocol for use with most of the common odontocete species (see Figure 1) that allows a fast diagnosis of acoustic trauma.



Figure 1: Periotic bone decalcification results from a harbor porpoise (*Phocoena phocoena*) after an exposition of 26 hours with the rapid decalcifier RDO®. While other decalcifiers need around three months for a similar complex size, RDO® allows obtaining very fast results.

TYMPANIC-PERIOTIC COMPLEX

The tympanic and periotic bones house the middle and inner ear, respectively. These structures are partially fused forming the tympanic-periotic complex (Figure 2). The tympanic periotic complex is surrounded by aerial sinuses called peribullar sinuses and suspended in the peribullar cavity through ligaments that hold it fixed and acoustically isolated it from the rest of the bones of the skull, except in sperm whales and some beaked whales, which present the tympanic-periotic complex partially fused to the temporal bone.



Revised May 15, 2014

Figure 2.- Computerized tomography images 3D reconstruction from the tympanic-periotic complex of a bottlenose dolphin *Tursiops truncatus* in ventral, medial and lateral vision from left to right, respectively.

Extraction

1. With small specimens, it is recommended to cut the head off the animal for an easier manipulation (Figure 3).

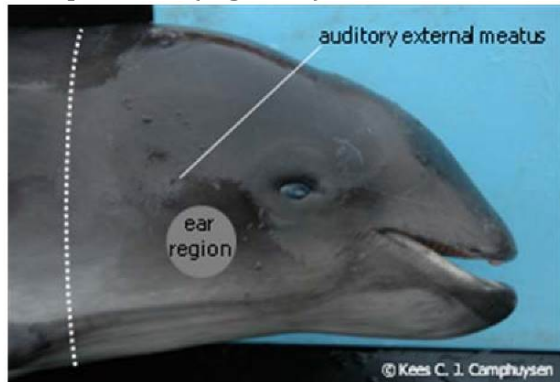


Figure 3.- The position of the tympanic-periotic complex and auditory external meatus is indicated. The dotted line marks the incision path to separate the head from the rest of the body. Alternatively, the larynx and upper digestive system can be extracted from the head to facilitate the access to the ears.

2. Taking into account the localization of the tympanic-periotic complex (Figures 3 and 4), the easiest way to access the ears is to carefully remove the lower jaw.

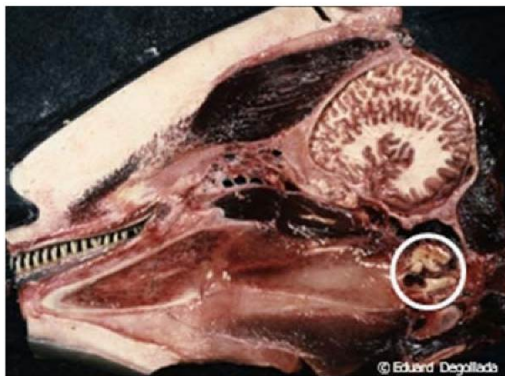

Figure 4.- Sagittal cut of a bottlenose dolphin head in which the location of the tympanic-periotic complex is indicated.

3. Situating the head in dorsal recumbancy and removing the soft tissues and ligaments (Figure 5) facilitates tympanic-periotic complex extraction.

Revised May 15, 2014

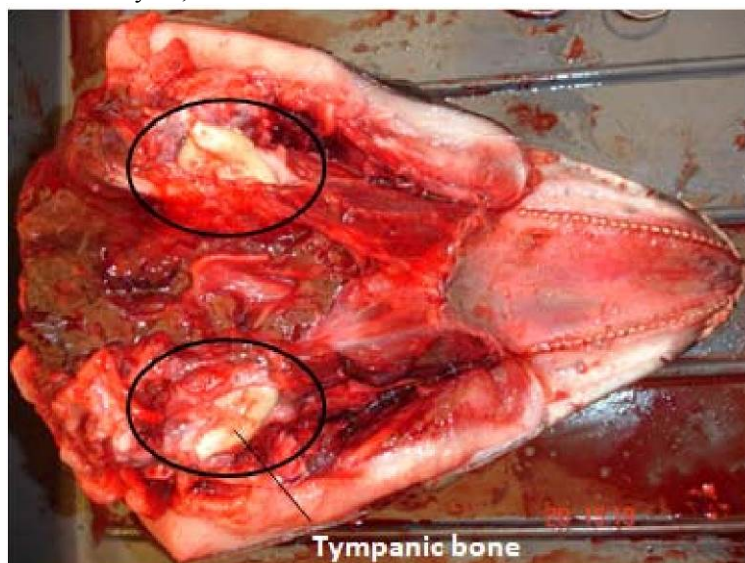


Figure 5.- Image taken during the necropsy of a *Phocoena phocoena*. This image reflects how the tympanic-periotic complex appears after removing the lower jaw (no effort has been made here to clean the area of extraction).

4. Incise gently around the tympanic-periotic complex with a small knife (a scalpel can be used for the final stage of the extraction) to cut the ligaments that maintain the ears in the paraotic sinus (see Figure 6).

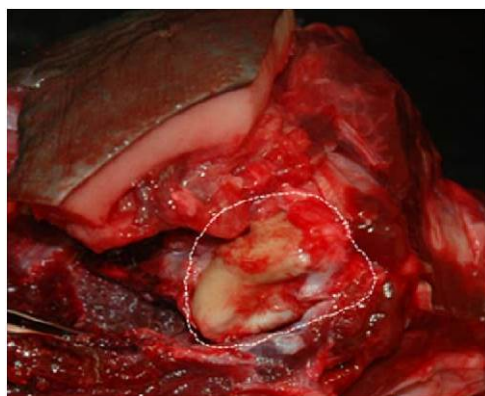


Figure 6.- Image taken during a *Phocoena phocoena* necropsy. The dotted line illustrates the location where the knife should be placed to extract the tympanic-periotic complex.

Fixation

5. At that stage, the ear could be fixed simply placing it in a fixative solution: glutaraldehyde 2.5% with 0.1M cacodylate buffer or 0.1M phosphate buffer (these solutions will be provided). The ears can also be injected with a mixture of paraformaldehyde 0.5% with glutaraldehyde 1% with phosphate buffer 0.1M or alternatively be injected with phosphate buffered formalin (pbf) 10%.

However, for a better result we recommend to follow the perfusion protocol.. If already experienced with the perfusion protocol, you may want to separate the periotic from the tympanic bone (Figure 7); cut the stapedial ligament and remove the stapes - if it does not come off easily, it helps passing a scalpel through the junction- make a small superficial

Revised May 15, 2014

hole through the oval and round window membranes; using a soft catheter. Progressively and very slowly (with very little pressure) introduce the fixative solution (glutaraldehyde 2.5% with 0.1M cacodylate buffer) through the oval window and the round window until the solution passes out (Figure 8).

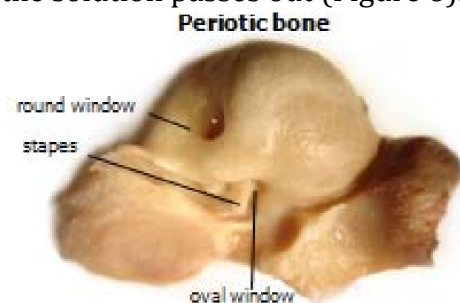


Figure 7.- Localization of the oval and round windows in the periotic bone.

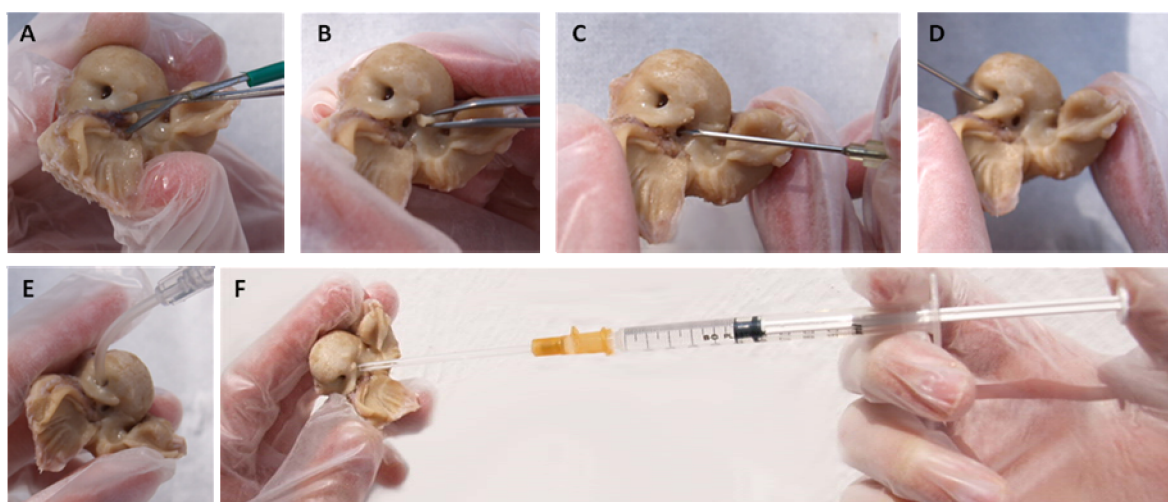


Figure 8. *Tursiops truncatus* periotic bone used to illustrate the injection process: A) cut of the stapediaal ligament, B) stapes extraction, C and D) create a small hole in the oval and round window membranes respectively, E and F) very slow and progressive perfusion (with very little pressure) of the fixative through the oval window and the round window. Continue until the solution leaks out.

Place the ears in jars that contain liquid fixative (see point 6).

Contact

You can send the ears by express mail to the following address:

Stephen Raverty and Maria Morell
Animal Health Center
1767 Angus Campbell Road
Abbotsford., BC
CANADA, V3G 2M3

For question, do not hesitate to contact Maria Morell at 604-445-2013 or 604-822-2373
email: morell@zoology.ubc.ca

Revised May 15, 2014

APPENDIX XVI: Barotrauma considerations and sampling protocol for gas bubbles

These instructions are a summary of the “protocol for gas sampling and analysis in marine mammals”. For further information please visit the link to this article:

<http://www.nature.com/protocolexchange/protocols/2299>

Material you need:

- 2-mL additive free glass tube (Kendall Monoject™ blood collection tube, ref: 301116)
- BD Vacutainer® one use holder (ref: 364815)
- Double pointed needle with a rubber barrier on the tube puncture side (BD Vacutainer® eclipse™ blood collection needle, ref: 368607).
- Disposable insulin syringes (BD Plastipak U-100 insulin ref: 329651).

Dissection

1. Carefully remove the skin and blubber minimizing damage to the major subcutaneous veins.
2. Examine the visible and larger subcutaneous veins for bubbles.
3. Take photos of veins with bubbles.
4. Sample bubbles*¹.

CRITICAL STEP: If pneumothorax is suspected, gas sampling could be done by using the Vacutainer® inserting the double pointed needle in between the ribs*². Do not open thoracic cavity!

5. Open first the abdominal cavity carefully (try not to cut medium to large size vessels).
6. Examine the mesenteric and renal veins as well as the lumbo-caudal venous plexus for bubbles.
7. Take photos of bubbles within vessels.
8. Sample bubble’s content “*in situ*” using the insulin syringes*¹.
9. Look for renal subcapsular emphysema.
10. Sample the subcapsular (gas) emphysema *in situ* using the Vacutainer® ².
11. Sample intestinal gases using the Vacutainer® ². Preferably take at least three samples from different locations.
12. Open thoracic cavity. If desired, ribs could be disarticulated except the first 3 or 4 cranial ones. These ribs should be cut at 1/3 from the vertebral articulation.
13. Examine the coronary vessels.
14. Take photos of vessels and bubbles.
15. Sample bubbles*¹.
16. Follow up with routine necropsy protocol.

CRITICAL STEP: do not cut any systemic vein or sample organs until this step is reached.

17. Separate the head from the body.
18. You might disarticulate the mandible to have a better access to the pteryoid sacs.
19. Sample pteryoid sacs using the Vacutainer® *².

CRITICAL STEP: do not open the sinuses before gas sampling.

*¹Gas sampling from bubbles in veins

Revised May 15, 2014

CRITICAL STEP: place the vein under water whenever possible to avoid atmospheric air contamination.

1. Sample each bubble with a new dispensable insulin syringe (BD Plastipak U-100 insulin)
2. Inject the content immediately into a new Vacutainer® each time.
3. Label the Vacutainer® with volume recovered and location of the bubble.

CRITICAL STEP: Use one new syringe and one new Vacutainer® for each bubble.

***2 Gas sampling from cavities (intestine, pterigoyd air sacs) and gas associated lesions (pneumothorax and subcapsular emphysema)**

1. Couple the Vacutainer® plastic holder to the double pointed needle
2. Insert the needle into the cavity
3. Push the Vacutainer® against the other end of the needle
4. Leave for a few seconds
5. Remove the Vacutainer®
6. Remove the needle

CRITICAL STEP: If any of these steps is not done following this sequence, atmospheric air contamination will occur.

CRITICAL STEP: If steps from 3-13 are not done carefully following this sequence, air contamination will occur.

Storage and transport

1. Store the samples at room temperature and atmospheric pressure.
2. Store blank tubes with the samples; one blank per sample or a minimum of 3 blanks per animal.
3. If samples need to be transported in a plane, they should travel within the passenger cabin to prevent dramatic changes in atmospheric pressure that might alter the vacuum tubes, or use a plastic housing resistant to negative pressures (PREVCO™ subsea housing).

Revised May 15, 2014

Appendix XVII: Dorsal fin measurement and collection request

Background:

The dorsal fin and detailed measurements of the fin and surrounding tissues are requested for use in the development of satellite tag attachment methods as part of a collaborative study. We have prioritized the list of requested materials and data from highest to lowest, as we recognize stranding responses are often limited in scope and resources. For more information contact Greg Schorr (gschorr@cascadiaresearch.org, 206.931.4638), Robin Baird (rwbaird@cascadiaresearch.org, 425.879.0360), Russ Andrews (RussA@alaskasealife.org) or Brad Hanson (brad.hanson@noaa.gov, 206.300.0282).
Note: Specimens must be freshly dead or only slightly decomposed (code 2).

1. Dorsal fin collection (highest priority)

- Remove the dorsal fin including the area 15cm (6 inches) anterior, posterior, and lateral to the dorsal fin, down to the sheath/muscle interface
- If possible, cover with A&D ointment (or similar non-petroleum based grease) prior to freezing. If covering is not possible, wrap in plastic and freeze.

Note: A FedEx number can be provided for shipment (contact Brad Hanson), or reimbursement of shipping cost can be arranged if necessary. Coolers or boxes can be returned upon request.

2. Blubber/muscle measurements (lower priority)

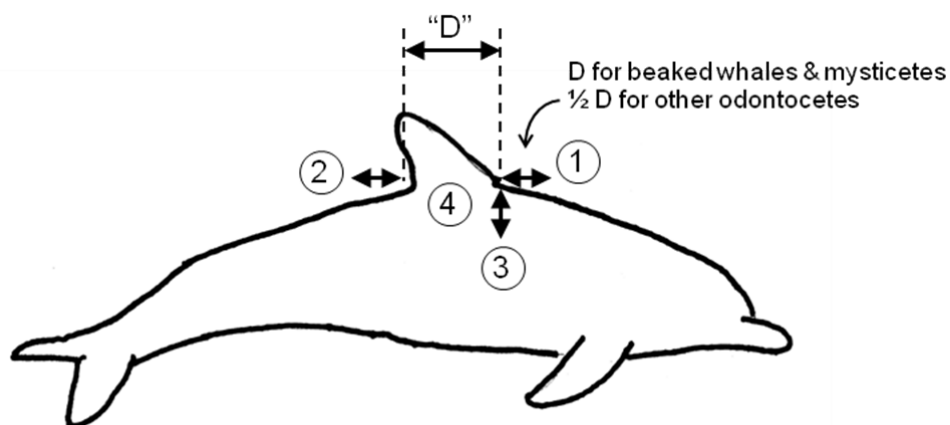
- Measure the length of the dorsal fin from the anterior and posterior insertion points (See figure 1, distance “D”).
- Measure and record thickness of the blubber and thickness of the muscle at the following sites:

Site 1: From the anterior insertion point of the dorsal fin, measure 1/2 of “D” towards the head.

Site 2: From the posterior insertion point of the dorsal, measure 1/2 of “D” caudally.

Site 3: On one side (either the left or right, whichever is more convenient), from the anterior insertion point, measure 1/2 “D” laterally towards the midline.

Figure 1:



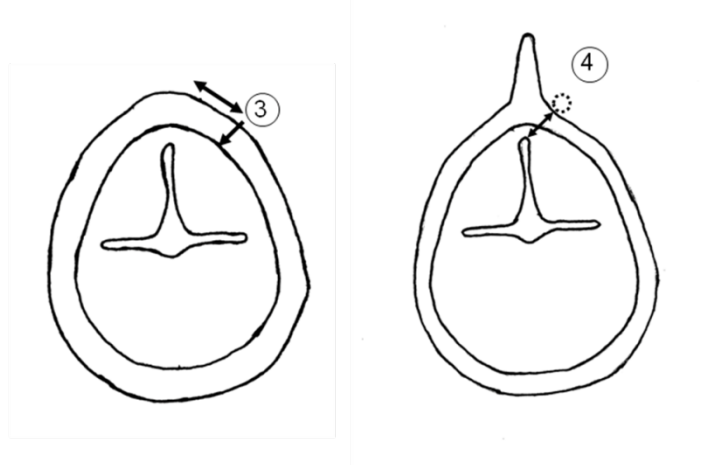
Revised May 15, 2014

3. Distance to dorsal process (lowest priority)

- Measure and record distance from epidermis to the dorsal process at the following site (figure 1 and 3):

Site 4: Measure 1/2 of the length of the dorsal between the anterior and posterior insertion point (figure 1 and 3). Site 4 should be on the body side of line between the anterior and posterior insertion point, not on the dorsal fin. Measure depth from the epidermis to the dorsal process at an angle perpendicular to the tangent of the body (figure 3).

Figures 2 (left) & 3 (right):



Revised May 15, 2014

APPENDIX XVIII: Archiving tissue samples

Archiving tissues is critical. Despite the attempt to include all desired sampling in this necropsy protocol, inevitably, there will be requests for further testing. Efforts have been made to set up killer whale tissue repositories in the United States and Canada. Both contain -80C freezers with back-up generators and recording of daily freezer temperatures.

Researchers that have collected tissues for archiving and would like to deposit them in a killer whale tissue bank should contact:

In the United States:

Dr. Brad Hanson, NOAA/NMFS/Northwest Fisheries Science Center, 2725 Montlake Blvd. E, Seattle, WA 98112, Office phone: 206-860-3220, Fax: 206-860-3475, Cell Phone 206-300-0282, Email: **Brad.Hanson@noaa.gov**

In Canada:

Dr. Stephen Raverty, Animal Health Center 1767 Angus Campbell Road, Abbotsford, BC, Canada V3M 2G3 Phone, work: 604-556-3003 Phone, work: 800-661-9903 Email: **Stephen.Raverty@gov.bc.ca**

Revised May 15, 2014

APPENDIX XIX: Lesion Description Form

Field ID: _____

Date: _____

LESION DESCRIPTION					PHOTOS			SAMPLES	
Lesion	Physical Location	Color Description	Comments	Size	on animal before sampling	of tissue extracted from animal	of animal after sampling	Histo	Other

Revised May 15, 2014

APPENDIX XX: NOAA Fisheries NW Region Killer Whale Stranding Protocol

November 2012

**Any stranding response with ESA-listed Southern Resident killer whales must be coordinated with NOAA Fisheries and authorized under the National Marine Mammal Health and Stranding Response Program Permit.*

Southern Resident killer whales were listed as endangered under the Endangered Species Act (ESA) in 2005. This protocol was developed to implement actions in the *Recovery Plan for Southern Resident Killer Whales* [Section 4.2.1] and establishes a protocol for coordinating response to a killer whale stranding event. Section 4.2.1 Information from all killer whale stranding events is important to inform recovery of Southern Residents. The protocol also contains steps to ensure compliance with the terms and conditions of the Marine Mammal Protection Act and Endangered Species Act Research and Enhancement Permit 932-1905 issued to the Marine Mammal Health and Stranding Response Program.

1. Confirm the stranding and species identification via photos, reliable source, or by having a network member respond to the stranding.
2. Please notify Kristin Wilkinson, NOAA Fisheries of the stranding at 206-526-4747 office, 206-550-6208 cell. Please provide as many details as possible and email photos to Kristin.Wilkinson@noaa.gov as soon as they are available.
 - a. If you are unable to reach Kristin or do not hear from her within 30 minutes please contact:
 - i. Brent Norberg 206-526-6550 office, 206-909-3771 cell
 - ii. Lynne Barre 206-526-4745 office, 206-718-3807 cell
 - iii. NOAA Fisheries will contact Teri Rowles at NOAA HQ (301-427-8448) once the stranding is confirmed, Brad Hanson (206-860- 3220 office, 206-300-2082 cell) at the Northwest Fisheries Science Center, NOAA Office for Law Enforcement (206-526-6133), and Department of Fisheries and Oceans (604-666-9965) as necessary.
3. If the stranding is confirmed as a killer whale please take photos of the animal, gather as much information as possible, and attempt to limit public access to the animal. If it can be done safely, it is important to secure the carcass of dead stranded killer whales so it is not taken out with the subsequent tide.
 - a. Photo Identification: Photos of the dorsal fin, saddle patch, eye patch or other identifying feature should be a priority (preferably left side) to assist with identifying type of killer whale (i.e., Southern Resident, Transient, or Offshore) and the individual identity of the whale. If possible, use of a white sheet as a backdrop behind the subject being photographed helps contrast these anatomic features.
 - b. Acoustic Identification: If the animal is alive and floating in the water, or accompanied by con-specifics and has not been identified to ecotype or individual, in addition to photographs it would be worthwhile to contact the Northwest Fisheries Science Center or Center for Whale Research (contacts listed below) to assist with obtaining an acoustic recording.

Revised May 15, 2014

4. Please collect information on location and site access for transfer via boat towing to closest boat ramp, removal by vehicle, or on-site necropsy.
5. NOAA Fisheries staff or the network coordinator will arrange a conference call if necessary to discuss the stranding. Participants may include experts from the following list of stranding network members and researchers that have specialized experience and have expressed an interest in participating in killer whale stranding response:

Name	Organization	Office	Cell
Brent Norberg	NOAA Fisheries	206-526-6550	206-909-3771
Lynne Barre	NOAA Fisheries	206-526-4745	206-718-3807
Kristin Wilkinson	NOAA Fisheries	206-526-4747	206-550-6208
Brian Gorman	NOAA Fisheries Public Relations	206-526-6613	206-604-6399
Brad Hanson	NWFSC	206-860-3220	206-300-0282
Dawn Noren	NWFSC	206-302-2439	206-423-0215
Candi Emmons	NWFSC	206-302-2432	206-251-2733
Joe Gaydos	SeaDoc Society	360-376-3910	360-914-1083
Stephen Raverty	BC Animal Health Center	604-556-3026	778-839-6916
John Calambokidis	Cascadia Research	360-943-7325	206-280-5320
Jessie Huggins	Cascadia Research	360-943-7325 x111	206-949-7924
Steve Jefferies	WDFW MMI	253-589-7235	253-380-4963
Dyanna Lambourn	WDFW MMI	253-589-7235	253-208-2427
Jen Olson	Whale Museum	360-378-4710 x27	360-472-1852
Dave Ellifrit	Center for Whale Research	360-378-5835	360-317-5287
Ken Balcomb	Center for Whale Research	360-378-5835	360-472-1707
Pete Schroeder	Global Research and Rescue	360 683-7437	
Susan Berta & Howie Garrett	Orca Network	1-866-672-2638	360-661-3739
Stephanie Norman	Central Puget Sound MMSN		206-321-0249
Local stranding network members covering area of stranding; see GIS maps for contact information.			
Inform Washington Department of Fish and Wildlife Law Enforcement 360-902-2936 if necessary.			
Inform US Coast Guard 206-587-0307 if necessary.			

6. If a conference call is necessary the following topics will be covered:
 - a. Identification of an on-site coordinator, this will be the local Stranding Coordinator (Letterholder), NOAA MMHSRP Staff, or other Permit designee. The on-site coordinator will oversee field response, data

Revised May 15, 2014

collection, and specimen disposition in consultation with the Permit Holder or designated Co-investigator.

- i. The On-site coordinator will be responsible for identifying key staff which would include:
 1. Lead Veterinarian – Responsible for conducting a health assessment on the animal and overall care during the networks response.
 2. Field Logistics – Responsible for responding to the stranding, managing volunteers and their roles at the site, and communicating relevant information to NOAA Fisheries.
 3. Data Manager – tracking specimen disposition and samples. Managing all data that is collected during the response and sharing with the appropriate parties.
 4. Necropsy Lead (if necessary) – lead and conduct the necropsy of the animal. Work with the data manager on specimen disposition and where samples will be sent for analysis.
 - b. Identify next steps for response (see Field Response below)
 - c. Communication with interested parties and preparation for media inquiries
7. Field Response
- a. For a dead animal:
 - i. A necropsy team will be formed to conduct a full necropsy. The necropsy lead should determine where the necropsy will take place (lab or field), the condition code (fresh, moderate, advanced), and what samples will be collected (including duplicates, samples to be archived, and samples for other researchers). The Killer Whale Necropsy and Disease Testing Protocol should be followed.
 1. The protocol can be found at:
<http://www.vetmed.ucdavis.edu/whc/pdfs/orcanecropsyprotocol.pdf>
 2. The protocol provides an equipment checklist, logistics and necropsy recommendations, resources, disease information, etc.
 - ii. Previous information on dead stranded killer whales is listed in the table below. This information may be requested by the media.
 - b. For a live animal:
 - i. Live animal response is logistically complex, potentially dangerous for personnel and the animal, and is expensive. Review the below considerations, determine the level of intervention necessary, and consider what resources your network has to offer for response.
 1. Considerations for assessing a live stranded cetacean:
 - a. Human safety is paramount and access to the animal should be restricted to qualified and authorized individuals.

Revised May 15, 2014

- b. Can the animal be moved from the beach into deeper water on the next high tide? When is the next high tide?
 - c. Is there any vessel support available to assist?
 - d. Is there a harness available to place the animal in to tow it out to deeper water?
 - i. Contact at Point Defiance Zoo and Aquarium is Dr. Karen Wolf at 253-404-3639 (Office) or 253-381-3115 (Cell)
 - ii. If a harness is not available one can be made out of Sampson line and some floats. See Figure 6.10 in *Marine Mammals Ashore, A Field Guide for Strandings*. Geraci & Lounsbury, 2005.
 - e. If the animal is going to stay on the beach for quite some time, keep the skin wet and if necessary, apply a salve to keep the skin from drying out.
 - i. An application of zinc oxide will protect skin from sun and windburn and help prevent dehydration. Skin already damaged should be kept moist, shaded, and protected with zinc oxide, antibiotic ointment, or petroleum jelly. (Geraci & Lounsbury, 2005). These products can be purchased at any drug store.
 - ii. In cold weather provide shelter from wind and precipitation, cover the extremities with a cloth dampened with mineral or vegetable oil. (Geraci & Lounsbury, 2005)
 - iii. In warm weather or sunny conditions, pay particular attention to keeping the appendages wet to facilitate heat loss (when safe and accessible.)
 - iv. Collect a blood sample and conduct hematology and clinical chemistry as soon as possible. Viral and bacterial swabs from the blowhole, mouth, rectum, and any lesions are also helpful. Gas analysis and an ultrasound may also be considered. Also consider taking a biopsy sample for genetics analysis.
2. Is there a tracking device available to monitor the animal after release?
 3. Network members must coordinate with NMFS/NWR to develop and implement a media plan for disseminating investigation information.

Revised May 15, 2014

- a. NOAA Public Relations, Brian Gorman (206-526-6613) and Janet Sears (206-526-6172) are available to assist.
8. After the necropsy of a dead animal or release of a live animal is complete, the stranding network group responsible for the geographic area where the event occurred should fill out a Level A report (and provide Level B data) for the stranding response and close the loop with media contacts and with everyone involved. A post-response de-briefing with the response team, NOAA Fisheries and other parties is recommended. During the de-briefing follow up actions such as sample analysis, writing reports, and final disposition of parts (i.e., skeleton) should be discussed.

Veterinarian Contacts in the Northwest Region for Killer Whale Assessment

Name	Organization	Location	Phone Number	Email
Dr. Joe Gaydos	SeaDoc Society	Orcas Island	360-376-3910 Office 360-914-1083 Cell	jkgaydos@ucdavis.edu
Dr. Stephanie Norman	Central Puget Sound MMSN & Marine-Med	Bothell, WA	206-321-0249	whaledoctor@gmail.com
Dr. Marty Haulena	Vancouver Aquarium	Point Roberts, WA	415-847-2781 US Cell 604-831-9550 CA Cell	Martin.Haulena@vanaqua.org
Dr. Kelly Helmick	Woodland Park Zoo	Seattle, WA	206-605-9040	kelly.helmick@zoo.org
Dr. Pete Schroeder	East Jefferson Co. MMSN	Sequim, WA	360-683-7437 Cell 360-670-6345	jpsmmra@olympen.com
Dr. Lesanna Lahner	Seattle Aquarium	Seattle, WA	206-707-2613	L.Lahner@seattleaquarium.org

***For killer whale strandings in other parts of the world**

New Zealand: Call Ingrid Visser, Orca Research Trust, ingrid@orca.org.nz, P.O. Box 402043, Tutukaka, Northland, 0153, New Zealand; + 64 (0)9 43 43 043 office / home , + 64 (0)274 727 627 mobile, (NZ only 0800 733 7722)

*Please contact us if you would like to be added as a contact person for your region.

Revised May 15, 2014

Appendix XXI: Protocol for examining killer whales for signs of human interaction

The following form should be used to examine killer whales for signs of human interaction. If you would like more information on the identification of human interaction in marine mammals or specific details regarding filling this form out, please see the complete paper from which this form originates:

Moore, K. T. and S. G. Barco. 2013. Handbook for recognizing, evaluating and documenting human interaction in stranded cetaceans and pinnipeds. NOAA Technical Memorandum, NOAA-TM-NMFS-SWFSC-510, 102 pp.

Available on-line at:

<http://swfsc.noaa.gov/publications/TM/SWFSC/NOAA-TM-NMFS-SWFSC-510.pdf>

Revised May 15, 2014

APPENDIX XXII: Fetal examination and sample management

Killer whale fetuses can be encountered as gestational fetuses within dead stranded pregnant females or as abortions or still births. Killer whale pregnancy can last 15-18 months. Determining if a small-sized animal is a neonate or a fetus can be difficult. Fetal decomposition can occur in utero or after expulsion. A fully developed, full sized animal can be delivered as a stillborn due to fetal death just prior to or at parturition. Because of these complexities, a thorough examination and sample collection is critical for fetal review.

A killer whale can be identified as fetus if:

- The developing fetus is present within a gravid uterus or birth canal or the abdomen of an adult female with an internal uterine rupture
- The fetal development is incomplete

Findings that **suggest** but do not confirm the animal as a fetus include:

- The body is less than 2.5m (8.2 feet) in length or 182 kg (400 pounds) in mass.
- Gastric content includes amniotic fluid and no milk
- Fetal folds are present

Taking a history on a fetus:

1. Maternal information including age, overall health, past pregnancies and their outcomes as known
2. Environmental situation including weather and conspecific events – is aggression/trauma a concern?
3. Paternal identity or possibilities
4. Any observed situation related to abortion – time/character of anorexia, contractions, straining, delivery complications, additional cases

Fetal/Tissue Examination:

1. Collect placenta, fetus, and amniotic fluid
2. Measure fetal length, weight, the distance between the eyes, note developmental features, estimate degree of decomposition (fresh, mild, moderate, severely deteriorated, mummified)
3. Examine the skin for meconium (green or orange) staining. Likewise, look for tan discoloration of the trachea and bronchi suggesting meconium inhalation.
4. Examine the placenta for completeness of expulsion. If the placenta is presented in sections, try to piece together to form a complete membrane. Weigh, measure the length and # twists in the umbilical cord. Extra support can be found at : <http://placentation.ucsd.edu/killerwhalefs.htm>

Specific points of examination:

Note: any abnormalities, photograph and sample for formalin

1. Observe for any malformations or organ abnormalities (when something does not form)

Revised May 15, 2014

2. Observe for any swelling/edema or hemorrhage – especially in the head/neck region that might suggest dystocia
3. Specifically observe the umbilicus for swelling/hemorrhage
4. Observe ribs and skull for swelling/fractures/irregularities
5. Observe organs for irregularity, firmness, necrosis, meconium staining, or abscesses
6. Examine brain for completeness; rule out hydrocephalus
7. Observe placenta for thickening, thinning, or discoloration
8. Specifically note the character of gastric contents – amniotic fluid versus curdled milk

Collection of Fetal samples for freezing/ancillary testing:

Abdominal/thoracic fluid (5 ml)	Spleen
Blood (3-5ml)	Thymus
Brain	Tissue pool (liver, spleen, lung, brain) in viral transport media
Gastric fluid (5-10 ml)	Tissue pool (liver, spleen, lung, brain) in RNA later
Kidney	Umbilical cord/placenta
Liver	
Lung	
Pericardial fluid (3ml)	

Fetal samples for culture:

- Stomach content – aerobic, anaerobic, fungal, and *Campylobacter* sp. cultures
- Liver – aerobic culture
- Lung - aerobic culture
- Umbilicus – aerobic
- Other cultures as indicated by gross findings

Fetal samples for 10% neutral buffered formalin:

brain	parathyroid
bladder	placenta (see exam details below)
colon/rectum	skeletal muscle
gonads	skin
esophagus	spleen
heart	stomach
intestines	trachea
kidney	thymus
larynx	thyroid
liver	tonsil
lung pituitary gland	umbilicus
lymph nodes	

Placental exam:

1. Save sections of placenta, amniotic sac, and umbilicus in 10% neutral buffered formalin
2. Save two 10 x 10cm sections of placenta frozen in whirl paks
3. Save small section (1cm x 1cm – cut into fragments) of placenta in RNA later and freeze
4. Save small section in EM fixative (Gluteraldehyde or Karnovski's solution)

Revised May 15, 2014

APPENDIX XXIII: Morphometric analysis of stranded killer whales

Note: If there are time or constraints or safety issues, please collect at least the data points in **BOLD**

Observer _____ Date _____

Identification number _____ Gender _____ Weight _____

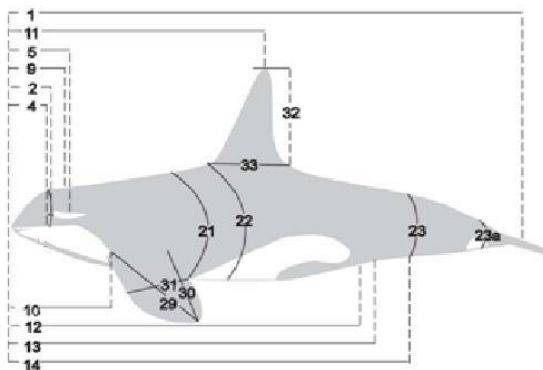
MEASUREMENTS, BODY (specify units of measure used _____)

1	Total straight length, snout to notch		13	Snout to genital slit	
2	Snout to center of eye (left)		14	Snout to anus	
3	Length of gape (left)		15	Eye to blowhole (center)(left)	
4	Snout to apex of melon		16	Projection of the lower jaw	
5	Snout to ear (left)		17	Blubber thickness*, mid dorsal	
6	Center of eye to ear (left)		18	Blubber thickness*, mid lateral	
7	Center of eye to angle of mouth		19	Blubber thickness*, mid ventral	
8	Center of eye to eye (curved - brow)		20	Girth at eye	
9	Snout to center of blowhole		21	Girth at axilla	
10	Snout to flipper (left)		22	Girth at leading edge of dorsal	
11	Snout to tip of dorsal fin		23	Girth at anus	
12	Snout to center of umbilicus		23a	Girth _____ cm before notch	

*Blubber thickness is measured at line 22- just cranial to the dorsal fin

MEASUREMENTS, APPENDAGES (specify units of measurement _____)

29	Flipper length (ant) (left)		33	Length of dorsal fin base	
30	Flipper length (post) (left)		34	Width of flukes (straight)	
31	Maximum width of flipper (left)		35	Length of flukes (left)	
32	Height of dorsal fin		36	Depth of fluke notch	



Revised May 15, 2014

APPENDIX XXIV: Gross pathology data recording form**Event Information**

Stranding date: _____

Recovery date: _____

Euthanized / Died

Date & time of death: _____

Necropsy date & time: _____

Storage prior to necropsy: _____

Stranding location: _____

Lat/Long: _____ N / _____ W

Animal Info

Sex: M / F / CBD

Length: _____ cm / in / ft

Weight: _____ lbs / Kg

Pup / Calf / YOY / Sub-adult / Adult / CBD

Condition at stranding: 1 2 3 4 5 6

Condition at necropsy: 1 2 3 4 5 6

Human Interaction: Yes / No / CBD

Mass Stranding: Yes / No

Number of animals: _____

Brief History:

Revised May 15, 2014

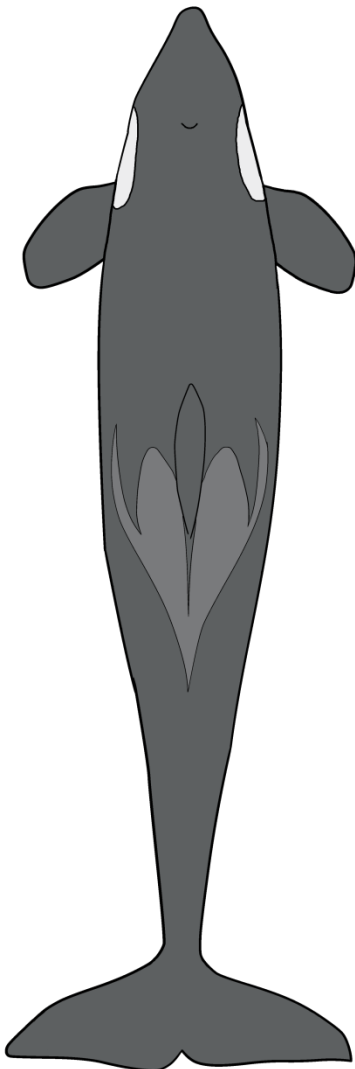
Necropsy Observations: Please note general observations of color, condition, textures, etc. even when utilizing NA= not applicable, NE= not examined, NSF= no significant findings, NVL= no visible lesions. List weights (g) next to each organ examined.

External Exam (Please note all lesions and if sections of animal are visible or obstructed – typically due to inability to move/rotate for viewing).

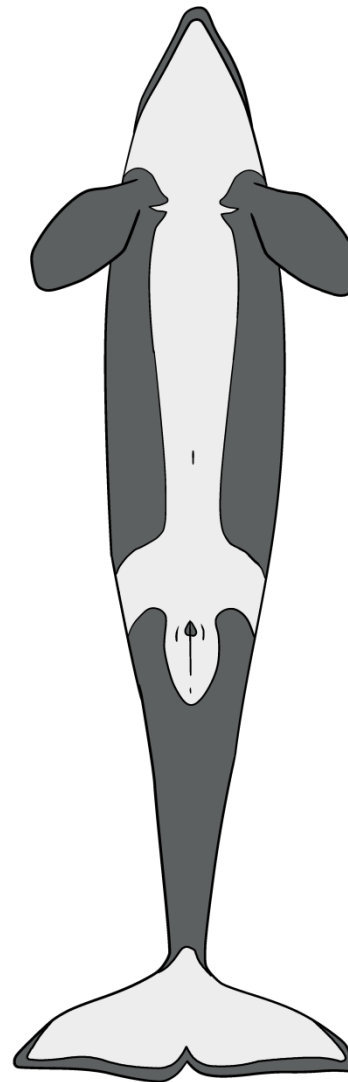
Body Condition: robust / thin / emaciated / CBD

Skin (fetal folds?, color, condition, wounds, scars, parasites – please diagram all changes):

Dorsal surface:




Ventral surface:




Revised May 15, 2014

Right side:



Left side:



Blowhole:

Mouth (tongue, teeth)/ Mucous membranes (color):

Eyes (discharge, color, ruptures): **(R)** **(L)**

Ears: **(R)** **(L)**

Revised May 15, 2014

Genital slit/anus/mammary openings/umbilicus:

Musculoskeletal system (bones, joints, muscles)

Blubber:

Diaphragm:

Skeletal:

Circulatory System

Pericardium:

Heart: (weight - kg)

Vessels:

Pulmonary System

Larynx:

Trachea:

Bronchi:

Revised May 15, 2014

Lungs (color, condition, edema, congestion, consolidation, granulomas, emphysema, lesions):

(R)(Weight kg)

(L)(Weight kg)

Tracheobronchial Lymph:

Gastrointestinal System

Esophagus:

Stomach (contents, ulcers, mucosa, parasites):

Small Intestine:

Large Intestine/colon/anus:

Peritoneum, mesentery, omentum:

Hepatic / Pancreatic

Liver (weight kg, color, congestion, lesions, size):

Bile Duct / Pancreaticoduodenal duct (color, amount):

Revised May 15, 2014

Pancreas:

Associated Lymph nodes:

Urinary / Reproductive Systems

Kidneys (reniculi differentiation, color, condition):

(R)(weight kg)

(L)(weight kg)

Bladder:

Testes / Ovaries: Immature / Mature

(R) Weight: kg, Lx W x H cm:

(L) Weight: kg, Lx W x H cm:

Mammary glands:

Uterus / Cervix / Vagina:

Pregnant: Y / N / NA (male) / CBD

Lymphatic System

Spleen (weight kg):

Scapular Lymph node:

Revised May 15, 2014

Thoracic cavity:

Internal Parasites (location, type, #)

SUMMARY- Differential Diagnosis from Gross Exam:

CARCASS DISPOSITION:

Soft tissue:

Skeleton:

PROSECTORS (list names and primary prosector signature)

SAMPLES/Disposition (Use attached list)

PHOTOS/VIDEO

Camera	Roll#	Frames:	Description:
---------------	--------------	----------------	---------------------

Revised May 15, 2014

APPENDIX XXV: Checklist - tissues to collect from a Code 2 or 3 killer whale carcass

Definition of Code 2: Freshly dead animal; skin firm, organs fresh

Definition of Code 3: Moderate decomposition; skin firm, body swelling, skin deterioration, often advanced predation, organs red and soft but discernible

Tissue	Histopathology	Culture swab	Dry swab	Ancillary testing	Cytology
Skin, multiple sites	<input type="checkbox"/> <input type="checkbox"/> <input type="checkbox"/>			<input type="checkbox"/>	
Blubber	<input type="checkbox"/>			<input type="checkbox"/> <input type="checkbox"/> <input type="checkbox"/>	
Dorsal fin				Intact <input type="checkbox"/>	
Head				Intact <input type="checkbox"/>	
Eye	1 globe <input type="checkbox"/>			5-10 ml <input type="checkbox"/>	
Conjunctiva	<input type="checkbox"/>	<input type="checkbox"/> <input type="checkbox"/>	<input type="checkbox"/>		
Ears				Intact <input type="checkbox"/>	
Ear, fat	<input type="checkbox"/>				
Blowhole	<input type="checkbox"/>	<input type="checkbox"/> <input type="checkbox"/> <input type="checkbox"/> <input type="checkbox"/>	<input type="checkbox"/>		Scrape <input type="checkbox"/>
Mandible (fat)	<input type="checkbox"/>			Intact <input type="checkbox"/>	
Teeth (1-2)				Intact <input type="checkbox"/>	
Brain- cerebrum	<input type="checkbox"/> <input type="checkbox"/> <input type="checkbox"/>	<input type="checkbox"/>		<input type="checkbox"/> <input type="checkbox"/> <input type="checkbox"/> <input type="checkbox"/>	
Brain- cerebellum	<input type="checkbox"/> <input type="checkbox"/> <input type="checkbox"/>			<input type="checkbox"/> <input type="checkbox"/>	
Brain- brainstem	<input type="checkbox"/>			50 gm <input type="checkbox"/>	
Pituitary gland	<input type="checkbox"/>			half <input type="checkbox"/>	
Spinal cord	Thoracic <input type="checkbox"/> Lumbar <input type="checkbox"/>			Thoracic <input type="checkbox"/> <input type="checkbox"/> Lumbar <input type="checkbox"/> <input type="checkbox"/>	
Brachial plexus	<input type="checkbox"/>				
Oral mucosa	<input type="checkbox"/>				
Oropharynx	<input type="checkbox"/>	<input type="checkbox"/>	<input type="checkbox"/>		
Tonsil	<input type="checkbox"/>			<input type="checkbox"/> <input type="checkbox"/>	
Tongue	<input type="checkbox"/>			50 gm <input type="checkbox"/> <input type="checkbox"/>	
Lymph node, multiple sites	<input type="checkbox"/> <input type="checkbox"/>	<input type="checkbox"/> <input type="checkbox"/>	<input type="checkbox"/>	50 gm <input type="checkbox"/> <input type="checkbox"/>	
Trachea	<input type="checkbox"/>	<input type="checkbox"/>	<input type="checkbox"/>	5 cm <input type="checkbox"/>	
Thyroid gland	<input type="checkbox"/>			1 whole <input type="checkbox"/> <input type="checkbox"/>	
Parathyroid gland	<input type="checkbox"/>			<input type="checkbox"/>	
Thymus	<input type="checkbox"/>			50 gm <input type="checkbox"/> <input type="checkbox"/> <input type="checkbox"/>	

Revised May 15, 2014

Tissue	Histopathology	Culture swab	Dry swab	Ancillary testing	Cytology
Bronchus	<input type="checkbox"/>	<input type="checkbox"/>	<input type="checkbox"/>	5 cm <input type="checkbox"/>	
Lung	<input type="checkbox"/> <input type="checkbox"/>	<input type="checkbox"/> <input type="checkbox"/> <input type="checkbox"/>	<input type="checkbox"/>	50 cm <input type="checkbox"/> <input type="checkbox"/>	
Heart blood				50 ml <input type="checkbox"/>	
Pericardium	<input type="checkbox"/>	<input type="checkbox"/>		50 gm <input type="checkbox"/>	
Pericardial fluid				10 ml <input type="checkbox"/>	<input type="checkbox"/>
Heart	<input type="checkbox"/> <input type="checkbox"/> <input type="checkbox"/>			50 gm <input type="checkbox"/>	
Aorta and vena cava	<input type="checkbox"/>				
Diaphragm	<input type="checkbox"/>			100 gm <input type="checkbox"/>	
Liver	<input type="checkbox"/> <input type="checkbox"/>			100 gm <input type="checkbox"/> <input type="checkbox"/> <input type="checkbox"/>	
Bile				10 ml <input type="checkbox"/>	<input type="checkbox"/>
Spleen	<input type="checkbox"/> <input type="checkbox"/>	<input type="checkbox"/>		<input type="checkbox"/> <input type="checkbox"/> <input type="checkbox"/>	
Pancreas	<input type="checkbox"/>			50 gm <input type="checkbox"/>	
Stomach	<input type="checkbox"/> <input type="checkbox"/>	<input type="checkbox"/>		Ingesta <input type="checkbox"/> <input type="checkbox"/>	
Small intestine	<input type="checkbox"/> <input type="checkbox"/>	<input type="checkbox"/> <input type="checkbox"/>		Ingesta <input type="checkbox"/> <input type="checkbox"/>	
Colon	<input type="checkbox"/>	<input type="checkbox"/> <input type="checkbox"/> <input type="checkbox"/>		Ingesta <input type="checkbox"/>	
Adrenals	<input type="checkbox"/> <input type="checkbox"/>			50 gm <input type="checkbox"/>	
Kidney	<input type="checkbox"/> <input type="checkbox"/>			100 gm <input type="checkbox"/> <input type="checkbox"/> <input type="checkbox"/>	
Ureter	<input type="checkbox"/>			<input type="checkbox"/>	
Urine				50 ml <input type="checkbox"/> <input type="checkbox"/>	
Urinary bladder	<input type="checkbox"/>			<input type="checkbox"/>	
Umbilicus	<input type="checkbox"/>	<input type="checkbox"/>			
Mammary gland	<input type="checkbox"/>	<input type="checkbox"/>	<input type="checkbox"/>	100 gm <input type="checkbox"/>	Aspirate <input type="checkbox"/>
Milk				50 ml <input type="checkbox"/>	
Genital slit	<input type="checkbox"/>	<input type="checkbox"/> <input type="checkbox"/>	<input type="checkbox"/>		
Urogenital canal	<input type="checkbox"/>	<input type="checkbox"/>	<input type="checkbox"/>		
Vagina	<input type="checkbox"/>	<input type="checkbox"/> <input type="checkbox"/>	<input type="checkbox"/>		
Uterus	<input type="checkbox"/>	<input type="checkbox"/> <input type="checkbox"/>	<input type="checkbox"/>	50 cm <input type="checkbox"/>	
Ovary	<input type="checkbox"/>	<input type="checkbox"/>	<input type="checkbox"/>	Intact corpora <input type="checkbox"/>	
Oviduct	<input type="checkbox"/>			2-4 cm <input type="checkbox"/>	
Penis/testes	<input type="checkbox"/>	<input type="checkbox"/> <input type="checkbox"/>	<input type="checkbox"/>		
Accessory sex glands	<input type="checkbox"/>				
Skeletal muscle	<input type="checkbox"/>			100 gm <input type="checkbox"/> <input type="checkbox"/> <input type="checkbox"/>	
Joint fluid		<input type="checkbox"/>			<input type="checkbox"/>
Rib/Bone marrow	<input type="checkbox"/>			100 gm <input type="checkbox"/>	<input type="checkbox"/>
Peripheral nerve	<input type="checkbox"/>				

Revised May 15, 2014

APPENDIX XXVI: Checklist - tissues to collect from a Code 4 killer whale carcass

Definition of Code 4: Advanced decomposition; organs difficult to clearly discern, skin sloughing, often swollen and expelled GI tract or repro organs

Tissue	Histopathology	Culture swab	Dry swab	Ancillary testing	Cytology
Skin, multiple sites	<input type="checkbox"/> <input type="checkbox"/> <input type="checkbox"/>			<input type="checkbox"/>	
Blubber	<input type="checkbox"/>			<input type="checkbox"/> <input type="checkbox"/> <input type="checkbox"/>	
Dorsal fin				Intact <input type="checkbox"/>	
Head				Intact <input type="checkbox"/>	
Conjunctiva	<input type="checkbox"/>	<input type="checkbox"/> <input type="checkbox"/>	<input type="checkbox"/>		
Ears				Intact <input type="checkbox"/>	
Blowhole	<input type="checkbox"/>	<input type="checkbox"/>	<input type="checkbox"/>		Scrape <input type="checkbox"/>
Teeth (1-2)				Intact <input type="checkbox"/>	
Brain- general	<input type="checkbox"/> <input type="checkbox"/> <input type="checkbox"/>	<input type="checkbox"/>		<input type="checkbox"/> <input type="checkbox"/> <input type="checkbox"/> <input type="checkbox"/>	
Oral mucosa	<input type="checkbox"/>				
Oropharynx	<input type="checkbox"/>	<input type="checkbox"/>	<input type="checkbox"/>		
Tonsil	<input type="checkbox"/>			<input type="checkbox"/> <input type="checkbox"/>	
Tongue	<input type="checkbox"/>			50 gm <input type="checkbox"/> <input type="checkbox"/>	
Lymph node, multiple sites	<input type="checkbox"/> <input type="checkbox"/>	<input type="checkbox"/> <input type="checkbox"/>	<input type="checkbox"/>	50 gm <input type="checkbox"/> <input type="checkbox"/>	
Trachea	<input type="checkbox"/>	<input type="checkbox"/>	<input type="checkbox"/>	5 cm <input type="checkbox"/>	
Thyroid gland	<input type="checkbox"/>			1 whole <input type="checkbox"/> <input type="checkbox"/>	
Parathyroid gland	<input type="checkbox"/>			<input type="checkbox"/>	
Thymus	<input type="checkbox"/>			50 gm <input type="checkbox"/> <input type="checkbox"/> <input type="checkbox"/>	
Lung	<input type="checkbox"/> <input type="checkbox"/>	<input type="checkbox"/> <input type="checkbox"/>	<input type="checkbox"/>	50 cm <input type="checkbox"/> <input type="checkbox"/>	
Heart	<input type="checkbox"/> <input type="checkbox"/> <input type="checkbox"/>			50 gm <input type="checkbox"/>	
Aorta and vena cava	<input type="checkbox"/>				
Diaphragm	<input type="checkbox"/>			100 gm <input type="checkbox"/>	
Liver	<input type="checkbox"/> <input type="checkbox"/>			100 gm <input type="checkbox"/> <input type="checkbox"/> <input type="checkbox"/>	
Spleen	<input type="checkbox"/> <input type="checkbox"/>	<input type="checkbox"/>		<input type="checkbox"/> <input type="checkbox"/> <input type="checkbox"/>	

Revised May 15, 2014

Tissue	Histopathology	Culture swab	Dry swab	Ancillary testing	Cytology
Spleen	<input type="checkbox"/> <input type="checkbox"/>	<input type="checkbox"/>		<input type="checkbox"/> <input type="checkbox"/> <input type="checkbox"/>	
Pancreas	<input type="checkbox"/>			50 gm <input type="checkbox"/>	
Stomach	<input type="checkbox"/> <input type="checkbox"/>	<input type="checkbox"/>		Ingesta <input type="checkbox"/> <input type="checkbox"/>	
Small intestine	<input type="checkbox"/> <input type="checkbox"/>	<input type="checkbox"/> <input type="checkbox"/>		Ingesta <input type="checkbox"/> <input type="checkbox"/>	
Colon	<input type="checkbox"/>	<input type="checkbox"/> <input type="checkbox"/> <input type="checkbox"/>		Ingesta <input type="checkbox"/>	
Adrenals	<input type="checkbox"/> <input type="checkbox"/>			50 gm <input type="checkbox"/>	
Kidney	<input type="checkbox"/> <input type="checkbox"/>			100 gm <input type="checkbox"/> <input type="checkbox"/> <input type="checkbox"/>	
Urine				50 ml <input type="checkbox"/> <input type="checkbox"/>	
Urinary bladder	<input type="checkbox"/>			<input type="checkbox"/>	
Umbilicus	<input type="checkbox"/>	<input type="checkbox"/>			
Mammary gland	<input type="checkbox"/>	<input type="checkbox"/>	<input type="checkbox"/>	100 gm <input type="checkbox"/>	Aspirate <input type="checkbox"/>
Genital slit	<input type="checkbox"/>	<input type="checkbox"/> <input type="checkbox"/>	<input type="checkbox"/>		
Vagina	<input type="checkbox"/>	<input type="checkbox"/> <input type="checkbox"/>	<input type="checkbox"/>		
Uterus	<input type="checkbox"/>	<input type="checkbox"/> <input type="checkbox"/>	<input type="checkbox"/>	50 cm <input type="checkbox"/>	
Ovary	<input type="checkbox"/>	<input type="checkbox"/>	<input type="checkbox"/>	Intact corpora <input type="checkbox"/>	
Penis/testes	<input type="checkbox"/>	<input type="checkbox"/> <input type="checkbox"/>	<input type="checkbox"/>		
Accessory sex glands	<input type="checkbox"/>				
Skeletal muscle	<input type="checkbox"/>			100 gm <input type="checkbox"/> <input type="checkbox"/> <input type="checkbox"/>	
Rib/Bone marrow	<input type="checkbox"/>			100 gm <input type="checkbox"/>	<input type="checkbox"/>
Peripheral nerve	<input type="checkbox"/>				

Revised May 15, 2014

APPENDIX XXVII: Checklist - tissues to collect from a Code 5 killer whale carcass

Definition of Code 5: Severe decomposition; Skeletal remains with associated soft tissue remnants

Tissue	Histopathology	Culture swab	Dry swab	Ancillary testing	Cytology
Skin, multiple sites	<input type="checkbox"/>			<input type="checkbox"/>	
Blubber				<input type="checkbox"/>	
Ears				Intact <input type="checkbox"/>	
Skeletal muscle				<input type="checkbox"/>	
Teeth (1-2)				Intact <input type="checkbox"/>	
Rib/Bone marrow	<input type="checkbox"/>			<input type="checkbox"/>	
Skull/skeleton				<input type="checkbox"/>	

Revised May 15, 2014

Photo Identifier:

(Please cut this tool out and use it as a scale and identifier for photographs you take)

Animal ID#(s):**Sex:****Age class:****Stranding Location:****Necropsy date:****Prosector:**